

FALK FOUNDATION e.V.



Leinenweberstr. 5
79108 Freiburg
Germany


www.falkfoundation.org

© 2011 Falk Foundation e.V.
All rights reserved.

**Abstracts of Invited Lectures
Poster Abstracts**

Falk Symposium 177

**ENDOSCOPY LIVE BERLIN 2011
INTESTINAL DISEASE MEETING**



Berlin (Germany)
April 15 – 16, 2011

Scientific Organization:
H.-J. Schulz, Berlin (Germany)
T. Rösch, Hamburg (Germany)
P.D. Siersema, Utrecht (Netherlands)

CONTENTS

Page

Faculty

A. Adler, C. Bojarski, G. Costamagna, J. Devière, S. Faiss, L. Familiari, K. Gellert, F. Hagenmüller, J. Hochberger, P.N. Meier, H. Messmann, G. Niedobitek, G. Niemann, T. Ponchon, T. Rösch, E. Santo, P.D. Siersema and the Endoscopy-Team of Sana Clinic (OZK)

Update lecture upper GI endoscopy
P.D. Siersema, Utrecht

13 – 14

LIVE-Demonstration (Session I)

Chair:

L. Familiari, Messina; J.F. Riemann, Ludwigshafen;
H.-J. Schulz, Berlin; K. Wietfeld, Marl

Update in biliary endoscopy
G. Costamagna, Rome

15

LIVE-Demonstration (Session II)

Chair:

F. Hagenmüller, Hamburg; U. Pfeifer, Düsseldorf;
E. Santo, Tel Aviv; W. Veltzke-Schlieker, Berlin

LIVE-Demonstration (Session III)

Chair:

U. Beilenhoff, Ulm; C. Jürgensen, Berlin;
T. Rösch, Hamburg; F. Schreiber, Graz

Update pancreatic diseases
J. Mössner, Leipzig

16 – 18

LIVE-Demonstration (Session IV)

Chair:

R. Drossel, Berlin; S. Faiss, Hamburg;
J. Hochberger, Hildesheim; T. Hrnjak, Berlin

Session I

Small bowel diagnostics

Chair:

J.F. Riemann, Ludwigshafen
T. Rösch, Hamburg
F. Schreiber, Graz

Capsule technology – An overview (no abstract)

F. Hagenmüller, Hamburg

Capsule endoscopy and Crohn's disease

D. Hartmann, Ludwigshafen

21

Radiology of the small bowel – Which test?

C. Stroszczyński, Regensburg

22

Session II

Special topic enteroscopy

Chair:

A. Adler, Berlin
C. Ell, Wiesbaden
P.D. Siersema, Utrecht

Technical overview: Balloons, spiral and beyond

A. May, C. Ell, Wiesbaden

25

Algorithms for the investigation of intestinal diseases with
capsule endoscopy and double balloon enteroscopy

M.M. Delvaux, G. Gay, Vandœuvre-lès-Nancy

26 – 27

Therapeutic enteroscopy

K. Mönkemüller, Bottrop

28 – 29

Session III

Diagnosis and assessment of IBD

Chair:

B. Bokemeyer, Minden

F. Hartmann, Frankfurt

M. Zeitz, Berlin

Endoscopic surveillance in IBD: Who needs what and when?

D.C. Baumgart, Berlin

33 – 34

Colonoscopic surveillance: State of the art – Reduction of biopsies

M. Götz, Mainz

35 – 36

Endoscopic intervention in IBC neoplasia (no abstract)

H. Messmann, Augsburg

PSC – Diagnostic and therapeutic problems

P. Sauer, Heidelberg

37 – 38

Session IV

Technicalities of colonoscopy

Chair:

J. Hochberger, Hildesheim

M. Jung, Mainz

H.-J. Schulz, Berlin

New colonoscopes and capsules, HDTV and more (no abstract)

J. Devière, Bruxelles

Endoscopic microscopy – Where are we heading?

R. Bisschops, Leuven

41

Tricks to make colonoscopy easier (no abstract)

G. Schachschal, Hamburg

Session V

Colon cancer screening

Chair:

R. Drossel, Berlin

J.F. Riemann, Ludwigshafen

B. Wiedenmann, Berlin

Colonoscopy screening: Status in Europe

J.F. Riemann, Ludwigshafen

45 – 49

Which non-invasive filter tests?

C. Pox, Bochum

50 – 51

The missed cancer problem (no abstract)

S. Faiss, Hamburg

Session VI

Endoscopic therapeutic techniques in the colon

Chair:

J. Hochberger, Hildesheim

P. Neuhaus, Berlin

W. Schmitt, Munich

Advanced polypectomy, mucosectomy and ESD – How far have we come? (no abstract)

T. Ponchon, Lyon

Endoresection of early cancer: When and how? (no abstract)

W. Schmitt, Munich

Limitations of endotherapy: Surgical view (no abstract)

T. Schiedeck, Ludwigsburg

List of Chairpersons, Speakers and Scientific Organizers

53 – 57

Poster Abstracts

Esophagus / Stomach

1. Rare forms of esophagitis: Esophageal candidosis and actinomycosis
S. Maev, I. Lupasco, V.-T. Dumbrava (Chisinau, MOL)
2. Duodeno-gastro-esophageal reflux (DGER) in symptomatic GERD patients with cholecystectomy
S. Manea, E. Gologan, G. Balan (Iasi, RO)
3. Biodegradable oesophageal stents for refractory benign disease: A case series
S. Hazeldine, J. Wu, R. Law, R. Przemioslo (Bristol, GB)
4. Genotyping of *Helicobacter pylori* strains from endoscopic biopsy
S. Uzun, A. Aslan, M. Temiz, S. Hakverdi, B. Özcan, C. Gülec, E. Özkök (Hatay, Istanbul, TR)
5. The efficacy of triple therapy treatment with probiotics in eradicating *Helicobacter pylori* infection in gastroduodenal ulcers
I. Copaci, L. Micu, A.V. Ditoiu, M. Voiculescu (Bucharest, RO)
6. The occurrence of pathological changes in the gastric mucosa in patients taking antiplatelet agents
M. Korzonek, A. Biskupski, M. Brykczynski (Szczecin, PL)

Liver, Bile, Pancreas

7. Laparoscopic treatment for focal liver malformations
J. Pósn, Z. Szentkereszty, I. Takács, R. Kotán, L. Sasi Szabó, P. Sápy, L. Damjanovich (Debrecen, H)
8. Hepatobiliary complications in IBD
P. Mitruț, A.O. Mitruț, A. Marinas, A. Genunche-Dumitrescu, D. Badea, A. Enescu (Craiova, RO)
9. Factors that influence the initial successful endoscopic management for biliary stricture after living donor liver transplantation (LDLT)
J.Y. Kim, S.J. Eo, K.-H. Lee (Seoul, ROK)
10. Therapeutic ERCP application analysis in elderly patients with choledocholithiasis
B. Putnina, A. Pukitis (Riga, LV)
11. Endoscopic treatment of biliary obstruction due to alien bodies and parasites
V.I. Kolomyitsev, O. Kushniruk, M. Pavlovsky (Lviv, UKR)

12. A duodenal duplication cyst as a cause of pancreatitis in an adolescent girl
M. Laaß, K. Wieczorek, G. Hahn, G. Fitze (Dresden, D)
13. Analysis of clinical course in severe acute biliary and non-biliary pancreatitis: A comparative study
R. Kotán, J. Pósn, Z. Szentkereszty, L. Sasi Szabó, P. Sápy, L. Damjanovich (Debrecen, H)
14. Pancreatic pseudocysts: Long-term results of endoscopic and surgical treatment
O. Kushniruk, V.I. Kolomyitsev (Lviv, UKR)

Small Bowel

15. Celiac disease - A retrospective study
E. Gologan, G. Stefanescu, S. Manea, D. Achitei, R. Bocan, C. Motea, C. Ciobanu, G. Balan (Iasi, RO)
16. 3D-MAGMA: A novel way of measuring motility in infectious diarrhea (ID)
J. Felber, S. Paetzold, H. Richert, A. Stallmach (Jena, Altenburg, D)
17. Duodenal lymphangiectasia scoring system based on magnifying endoscopy with NBI
S. Belyavskaja, K. Marahovsky (Minsk, WR)
18. Excavated lesions in small bowel found during capsule endoscopy correlates with patient vital signs
A. Derovs, J. Derova, J. Pokrotnieks (Riga, LV)
19. Capsule endoscopy in protein losing enteropathy - Case report
G. Oracz, J. Kierkus, M. Dadalski, J. Ryzko (Warsaw, PL)
20. Therapeutic DBE: A bi-national, three-center experience
I. Jovanovic, K. Vormbrock, L.C. Fry, S. Djuranovic, M. Ugljesic, M. Zabielski, P. Malfertheiner, K. Mönkemüller (Bottrop, Magdeburg, D; Belgrade, SRB)
21. Ileum examination is not the rule during colonoscopy exam
A. Haidar, Y. Kardous, B. Aznag, A. Ouchieng, A. Zlate, F. Musat, C. Vasiliu, O. Panazan (Bucharest, RO)
22. Ileal biopsy in chronic diarrhea with normal appearing ileoscopy
A. Sayilir, M. Kurt, M. Kekilli, I.K. Onal, Y. Beyazit, N. Turhan, M. Ibis, M. Arhan (Ankara, TR)
23. An audit on the use of the SeHCAT test in chronic diarrheal illnesses
N. Patel, L. Davidson, S. Singh, K. Padmakumar (Manchester, Bolton, GB)
24. Whipple's disease and gastric cancer - Is there any relationship?
C. Searpe, A. Rosu, V. Sbarcea, M. Tenovici (Craiova, RO)

IBD

25. A contribution to the epidemiology of ulcerative colitis in Bulgaria
T. Karparova-Tuhchieva, P. Akrabova, V. Djurkov, V. Kuzmanov (Plovdiv, BG)
26. Is Crohn's disease a rare disease?
V. Kuzmanov, T. Karparova-Tuhchieva, P. Akrabova, V. Djurkov (Plovdiv, BG)
27. Clinical and endoscopic features of patients with ulcerative colitis
A. Stadnicki, E.I. Klimacka-Nawrot, A. Wolanska-Karut, I. Stadnicka, J. Kurek (Sosnowiec, Katowice, Jaworzno, PL)
28. Capsule endoscopy and pediatric IBD
O.V. Fedorova, E.N. Fedulova, G.V. Medyantseva (Nizhny Novgorod, R)
29. Effective to achieve mucosal healing with infliximab in pediatric patients with Crohn's disease
J. Kierkus, M. Dadalski, G. Oracz, M. Teisseyre, M. Woynarowski, J. Ryzko (Warsaw, PL)
30. Videocapsule and balloon-assisted enteroscopy in diagnosis of small bowel Crohn's disease
E.V. Ivanova, M.E. Timofeev, U.A. Kadnikova, E.D. Fedorov (Moscow, R)
31. Cinical challenge for physicians: Abdominal tuberculosis - Review of 21 cases
M. Ergün, M. Basaranoglu, B. Tunc, A. Ülker, N. Sasmaz (Ankara, TR)
32. Intestinal tuberculosis versus Crohn's disease - Differential diagnosis and treatment issues
S. Suci, C. Gheorghe, G. Becheanu (Bucharest, RO)
33. Five-year colonoscopic, histologic and immunohistochemical surveillance study in ulcerative colitis patients
O. Fratila, M. Puscasiu, G. Avram (Oradea, RO)
34. Adenomatous polyps incidence in ulcerative colitis – Comparative colonoscopic study with healthy population
T. Ilias, O. Fratila, O. Straciuc (Oradea, RO)
35. Safety and efficacy of endoscopic balloon dilation for colonic stenosis in Crohn's disease patients
C. Gheorghe, S. Suci, B. Cotruta (Bucharest, RO)
36. Surgical management of Crohn's disease in adults: Long-term results of a tertiary center
G. Nessar, M. Basaranoglu, N. Turhan, B. Tunc, A.E. Demirbag (Ankara, TR)

Colorectal Cancer Carcinoma

37. Predictive validity of an accreditation assessment of colonoscopy
E. Harrison, D. Rattehalli, N. Sagar, M.M. Ahmed, C.H. Lim (Birmingham, GB)
38. Assessment the risk of recurrence in colonic diverticulitis
P. Mitrut, A.O. Mitrut, A. Marinas, A. Genunche-Dumitrescu, A. Enescu, D. Badea (Craiova, RO)
39. The colorectal involvement in lymphoma
D. Badea, M. Badea, A. Genunche-Dumitrescu, A. Badea, L. Stefan (Craiova, RO)
40. Peutz-Jeghers syndrome
N. Taran, I. Lupasco, V.-T. Dumbrava (Chisinau, MOL)
41. Epidemiology of colorectal cancer in the centre of Romania
E.C. Rezi, A. Fraticiu, R.G. Mihaila (Sibiu, RO)
42. Colonoscopically monitoring of risk of recurrence after resection of colorectal carcinoma
A. Genunche-Dumitrescu, D. Badea, M. Badea, P. Mitrut (Craiova, RO)
43. The characteristics of non-curative endoscopic resection in early colon cancer
J.Y. Kim, S.J. Eo, D.K. Chang, Y.-H. Kim, P.-L. Rhee, J.J. Kim (Seoul, ROK)
44. Adherence to colorectal cancer (CRC) guidelines after polypectomy in a university hospital
B. Zimmer, J. Felber, A. Stallmach (Jena, D)

Gastrointestinal Bleeding

45. Impact of a routine weekend endoscopy service on patients presenting with upper gastrointestinal bleeding
A. Vaishnavi, C. Ash, S. Singh, K. Padmakumar (Bolton, GB)
46. Early gastric cancer (EGC) - An incidental finding in the upper GI bleeding. Case report
A. Bartkova, M. Liberda, O. Urban (Valasske Mezirici, Ostrava, CZ)
47. Rectorrhagia - The etiology and the clinical spectrum
D. Damian, C. Pojoga (Cluj-Napoca, RO)
48. Mechanism of action for Ankaferd Blood Stopper (ABS) in patients with gastrointestinal hemorrhages
Y. Beyazit, M. Basaranoglu (Ankara, TR)
49. Ankaferd hemostat for the management of upper gastrointestinal hemorrhages: A meta-analysis
M. Basaranoglu, Y. Beyazit (Ankara, TR)

50. Application of Ankaferd Blood Stopper for gastrointestinal system bleeding
M. Kurt, A. Sayilir, Y. Beyazit, M. Kekilli, I.K. Onal (Ankara, TR)
51. UK endoscopy trainees provide a significant quantity of service delivery
L.P. Griffiths, K. Dowler, R. Valori, P. Dunckley (Gloucester, GB)

Update lecture upper GI endoscopy

Peter D. Siersema, M.D., Ph.D.

Department of Gastroenterology and Hepatology, University Medical Center Utrecht, The Netherlands

Barrett's esophagus

Barrett's esophagus (BE) is a premalignant lesion predisposing to esophageal and gastroesophageal adenocarcinoma. The risk of esophageal adenocarcinoma is 30 to 40 times as high among patients with BE as among patients without this condition. The progression of BE may involve the development of low-grade dysplasia (LGD) and high-grade dysplasia (HGD) before the eventual development of cancer. BE is diagnosed in approximately 10 to 15% of patients with reflux who are undergoing endoscopy; it has also been reported in patients without chronic reflux symptoms, with a prevalence of 5.6% in one report of endoscopic screening. In a population-based study conducted in Sweden, BE was diagnosed in 1.6% of 3000 study participants. Risk factors for BE include advanced age, male sex, white race, symptoms of reflux, and obesity. In the last year some exciting studies have been performed regarding the diagnosis and treatment of BE.

Regarding the diagnosis of BE, it was found that a new endoscopic system, endoscopic trimodal imaging, which incorporates white-light high-resolution endoscopy, autofluorescence imaging and narrow-band imaging (NBI) in a community-based setting did not improve the overall detection of dysplasia compared with standard video endoscopy. Another finding was that standard and large-capacity forceps used with standard upper endoscopes produced biopsy samples that were at least as adequate as those obtained with jumbo forceps and therapeutic endoscopes in patients with BE. Moreover, brush cytology of BE was reported to have excellent specificity and good sensitivity for the detection of HGD/adenocarcinoma in BE but poor sensitivity for LGD. Although there was substantial concordance between cytology and histology for the detection of dysplasia, histology had a higher dysplasia detection rate and therefore the value of routine cytology in the surveillance of Barrett's esophagus is questionable.

Regarding the treatment of high-grade dysplasia or early adenocarcinoma in BE, it was reported that endoscopic treatment had lower morbidity than esophagectomy and similar survival during short-term follow-up, but required multiple procedures in most patients. Both treatments seem therefore appropriate options, but preservation of the esophagus using endoscopic therapy allows the option of a fundoplication for reflux control, perhaps further improving long-term quality of life. Moreover, in order to find the most optimal endoscopic treatment, focal endoscopic resection with radiofrequency ablation was found to achieve comparably high rates of complete eradication compared to stepwise complete endoscopic resection, with the latter being associated with a higher number of complications and therapeutic sessions. A combined endoscopic approach of focal endoscopic resection followed by radiofrequency ablation may thus be preferred.

Stents in the esophagus and stomach

Stents are increasingly being used to treat benign esophageal strictures, and benign ruptures and anastomotic leaks. In addition, they are still important in the treatment of dysphagia from malignancy. In 2010, some new esophageal stents have been introduced, i.e., partially or fully covered Evolution stents (Cook), and partially or fully covered Wallflex stents (Boston Scientific). The initial experience in malignancy was encouraging in terms of clinical success and low complication risk. Potential new indications in the esophagus include stents as bridge-to-surgery in malignancy, self-expanding plastic stents for the protection of surgical anastomoses after esophageal resection and as an alternative to balloon dilation in achalasia.

Another indication of stents include their use in gastric outlet obstruction due to malignancy as an alternative to a surgically performed gastrojejunostomy. It was however found that despite slow initial symptom improvement, gastrojejunostomy was associated with better long-term results and this should therefore be the treatment of choice in patients with a life expectancy of 2 months or longer. Because stent placement was associated with better short-term outcomes, this treatment is preferable for patients expected to live less than 2 months.

ESD in gastric cancer

Early gastric cancer is defined as invasion confined to the mucosa or submucosa, regardless of presence of regional lymph node metastasis. Endoscopic resection is beneficial for the treatment of early gastric cancer. The procedure is associated with a low risk of lymph node metastasis; it is also minimally invasive, safe, and convenient with respect to quality of life (QOL). Endoscopic resection, especially in endoscopic submucosal dissection (ESD), allows one-piece resection with tumor-free margins, even in cases of large and ulcerative lesions. The procedure also permits accurate histopathological examination and may prevent residual disease and local recurrence. It was found that endoscopic mucosal resection (EMR), even with curative resection, and incomplete resection after ESD have an increased risk of local recurrence.

Although the safety of ESD has been established, the procedure still has a relatively high complication rate for procedure-related bleeding (1.8–6.2%) and perforation (4.0–9.7%). It was recently reported that a resected specimen width of (> 40 mm) was the only significant factor associated with delayed bleeding. In early delayed bleeding (bleeding occurring on or before the fourth postoperative day), wide resected specimen and tumor location in the lower third of the stomach were significant risk factors. In late delayed bleeding (bleeding occurring after the fifth operative day), wide resected specimen, tumor location in the middle third of the stomach, hypertension, and high body mass index (> 25 kg/m²) were significant factors. Interesting endoscopic Doppler ultrasound could be of interest in the recognition and therefore prevention of bleeding after ESD.

Update in biliary endoscopy

Guido Costamagna, MD, FACC

Digestive Endoscopy Unit, Catholic University of Rome, Rome, Italy

Biliary endoscopy has rapidly enriched with new techniques in the last few years. Its current role includes direct diagnostic imaging, tissue sampling and therapy of many diseases of the pancreaticobiliary system. Indications for biliary endoscopy are increasing daily, besides the awareness for the risk of important complications. Since the first biliary sphincterotomy in 1974, endoscopic retrograde cholangiopancreatography evolved rapidly from purely diagnostic into almost exclusively operative procedure. The diagnostic utilization of endoscopic retrograde cholangiopancreatography has been replaced by other non invasive imaging techniques as magnetic resonance cholangiopancreatography. The current operative role of endoscopic retrograde cholangiopancreatography of the biliary system consists in management of common bile duct stones, drainage of malignant and benign biliary strictures, and management of postoperative bile leaks. Relatively new methods for biliary stones management are electrohydraulic lithotripsy combined with choledochoscope guidance and laser lithotripsy. Accessories, materials and medical equipment for endoscopic retrograde cholangiopancreatography have also evolved. At present there are nitinol stents with equilibrated axial and radial force for the drainage of benign and malignant biliary strictures. New types of nitinol stents for anastomotic biliary strictures (including liver transplantation) and biliary strictures due to chronic pancreatitis are under investigation. Drug-eluting stents with incorporated anti-tumor agents designed to improve patency and reduce the risk of tumor ingrowth are under investigation as well. Intraductal ultrasound, digital imaging analysis, fluorescence in situ hybridation, confocal laser endomicroscopy and optical coherence tomography are emerging, purely diagnostic endoscopic tools in biliary endoscopy. Direct visualization of the biliary mucosa and tissue sampling can be done with the last generation of cholangioscopes. These tools are promising specially for the “undetermined biliary strictures”. Biliary endoscopy in the past years has been modernized with new tools that allow early diagnosis and management of diseases of the pancreaticobiliary system. Endoscopic retrograde cholangiopancreatography is operator dependent, and require skilled endoscopists and significant expertise specially for emerging techniques. It is natural that all these new techniques are nourishing our enthusiasm, but now it is fundamental to understand which are the risks and benefits before going forward.

Address for correspondence:

Guido Costamagna, MD, FACC

Digestive Endoscopy Unit

Catholic University of Rome

Largo A. Gemelli, 8

00168 Rome

Italy

Update pancreatic diseases

Joachim Mössner
University of Leipzig, Germany

Pancreatic physiology

The pancreas is stimulated acutely by feeding via neuronal mechanisms. The vagus mediates a small cephalic phase. Vagal afferents are important. There are vagal-vagal reflexes. Acinar cells have M1 and M3 receptors. Acetylcholine is the main transmitter and stimulates acini, ducts, and islets. CCK is a peptide hormone of the gastrointestinal system and brain. It is synthesized by I-cells in the mucosa of small intestine and secreted from the first segment of the small intestine. Its release from I-cells is stimulated by oligopeptides, certain amino acids (phenylalanine), and fatty acids. Probably CCK releasing peptides present in pancreatic secretions and duodenal mucosa are involved. According to new data CCK-receptors exist on human acinar cells not only in rodents. Thus, CCK may stimulate enzyme secretion not only indirectly by acting on CCK-B-receptors on intrapancreatic nerves which release acetylcholine but also directly. Secretion is probably terminated by exit of food from upper small intestine, the so called ileal brake. PYY is one of probably several hormones and neurotransmitters involved in the ileal brake. In stimulus secretion coupling acetylcholine stimulates muscarinic receptors followed by the cascades in which phospholipase C, diacylglycerol, inositoltrisphosphate (IP3), calcium release from the endoplasmic reticulum, stimulation of protein kinase C etc. are involved. At least in rodents there are further membrane receptors on the acinar cell involved in enzyme secretion such as VIP, bombesin, CCK, secretin. VIP and secretin stimulate cyclic-AMP formation which leads to stimulation of protein kinase A. According to JA Williams et al. small GTP-binding proteins are molecular switches in the regulation of numerous cellular processes, including vesicular transport. The biochemical steps which lead to fusion of enzyme granules with the apical cell membrane are still not fully clarified.

Acute pancreatitis

There is still a controversial debate whether alcohol abuse may cause acute pancreatitis or whether alcohol induced pancreatitis is an attack of already chronic pancreatitis. Transient or permanently impacted gallstones in the papilla of Vater are the most frequent causes. We still do not know why most patients develop a rather mild disease, i.e. oedematous pancreatitis, and others a severe disease with haemorrhages, necrosis and potential multi-organ-dysfunction-syndrome (MODS). Early death is due to SIRS, late death to sepsis leading to MODS. We still lack a pancreas specific therapy treating the cause of the disease. Inactivation of trypsin by antiproteases may be beneficial in animal models. In human pancreatitis the start of this therapy may be too late, thus being not able to prevent the vicious cascade of pathogenetic events leading to MODS. Papillotomy is indicated in bile obstruction combined with or without cholangitis. Early papillotomy has probably no beneficial effects in the absence of obstruction or cholangitis. Most bile stones may have already passed the papilla spontaneously. The application of prophylactic antibiotics such as imipenem to prevent infection in necrotizing pancreatitis is still discussed controversially and probably not beneficial. Early enteral nutrition by tube feeding is standard and has substituted parenteral nutrition. A difficult task is to calculate and substitute the enormous fluid losses.

Chronic pancreatitis

Chronic pancreatitis is a mostly irreversible chronic inflammatory disease characterized by relapsing or chronic pain, complications such as pseudocysts and bile duct stenosis. Alcohol is still the leading cause. Smoking is a separate risk factor. However, our knowledge on additional genetic risk factors is still increasing.

The discovery of a mutation of the cationic trypsinogen gene (PRSS1) in patients with hereditary chronic pancreatitis supported Hans Chiari's theory that chronic pancreatitis is the result of autodigestion of the pancreas. Research had its focus on proteases and anti-proteases that are assembled in the digestive enzyme cascade, an approach that identified serine protease inhibitor, Kazal type 1 (SPINK1) as another pancreatitis gene. Aside the digestive enzyme cascade, CFTR that is responsible for cystic fibrosis, was investigated. An enrichment of CFTR variants in patients with chronic pancreatitis has been found. Further aspects in the field of genetics in chronic pancreatitis emerged in the last years. A variant of anionic trypsinogen (PRSS2) was found to be overrepresented in controls and protects against chronic pancreatitis. Additionally, variants of the calcium sensing receptor (CASR) seem to influence the pathogenesis in SPINK1 p.N34S carriers. Triplication and duplication of the trypsinogen locus represents a completely new disease causing mechanism that predisposes to chronic pancreatitis by a so-called gene dosage effect. Identification of chymotrypsin C (CTRC) displayed another reasonable candidate gene. Investigations of CTRC found low penetrance loss of function variants that diminish secretion and/or activity of CTRC and thereby contribute to the development of the disease. Taken together recent data further support the importance of a balanced digestive enzyme cascade in that trypsin captures a key role.

There is a lack of prospective, controlled, randomized studies comparing different treatment options such as medical treatment, interventional endoscopy and surgery. This may be due to the difficult compliance of alcoholics. There are quite a few excellent studies comparing various surgical procedures and one milestone study comparing pancreaticojejunostomy with endoscopically placed pancreatic duct stents which shows a superiority of surgery regarding pain relieve. In alcohol abusers and smokers the prognosis is more determined by the life style as by complications of pancreatitis and consequences of exocrine and endocrine insufficiency. Thus, one has to pay attention on smoking related cancers. The risk to die from pancreatic cancer is increased especially in patients with a course of the disease of many decades such as in hereditary pancreatitis.

Pancreatic cancer

Pancreatic cancer remains to be a dismal disease. Despite the fact that we more and more understand the genetic steps which finally lead to pancreatic cancer and metastases (PANIN concept: ductal pancreatic intraepithelial neoplasia: Her-2-neu, K-ras, p16, p53, DPC4, BRCA-2 mutations etc.) we are mostly not able to make an early diagnosis. In about 20% R-0-resection is still possible. However, most patients develop early recurrence or liver and distant metastases. The desmoplastic reaction of this tumor may be one of many further unknown reasons why chemotherapy is not very effective. Adjuvant therapy with gemcitabine is established and prolongues survival for some months. There is almost no 5-year survival. Thus, incidence equals prevalence. In metastatic disease addition of erlotinib, an EGFR-receptor inhibitor (so

called targeted therapy with a small molecule which inhibits tyrosine- kinase) to gemcitabine may prolong survival for a few weeks, however only in those patients who develop rash.

Address for correspondence:

Joachim Mössner, M.D.
Professor of Medicine
Universitätsklinikum Leipzig AöR
Department of Medicine, Dermatology & Neurology
Division of Gastroenterology & Rheumatology
Liebigstr. 20
04103 Leipzig
Germany
E-Mail: moej@medizin.uni-leipzig.de

Session I

Small bowel diagnostics

Capsule endoscopy and Crohn's disease

PD Dr. Dirk Hartmann
Klinikum Ludwigshafen, Germany

Crohn's disease is a lifelong disease, observed predominantly in the developed countries of the world. The disease is marked by frequent relapses and patients often undergo repeated investigations. Crohn's disease is a heterogeneous entity comprised of several different phenotypes and can affect the entire gastrointestinal tract. Until a decade ago, mucosal visualization of the small bowel was limited to the reach of the push enteroscope (excluding invasive and expensive intraoperative enteroscopy). The advent of capsule endoscopy is revolutionizing small bowel imaging and has major implications for diagnosis, classification, therapeutic decision making, and outcomes in management of Crohn's disease.

Studies have suggested that up to 30% of patients diagnosed with Crohn's disease will have only small bowel involvement. Capsule endoscopy is able to visualize all of the small bowel with minimal discomfort for the patient. The main disadvantages are to manoeuvre the capsule, the lack of therapeutic capabilities, and the risk of capsule retention due to strictures. Most patients have lesions located in the (neo)-terminal ileum accessible by ileocolonoscopy. Therefore, in all patients with suspected Crohn's disease, colonoscopy with inspection of the terminal ileum must be performed prior to capsule endoscopy. In patients with unexplained symptoms, capsule endoscopy is able to identify mucosal lesions compatible with Crohn's disease in whom conventional endoscopic and small bowel radiographic imaging modalities have been nondiagnostic.

There is no single, gold standard diagnostic test for Crohn's disease. The diagnosis is based on constellation of findings, including the history and physical examination, endoscopic and radiological features, and laboratory and pathology findings. Capsule endoscopy improves the clinician's ability to identify subtle lesions that may be associated with an initial presentation of Crohn's disease. No studies, to date, have defined precisely findings on capsule endoscopy that constitute a diagnosis of Crohn's disease. Therefore, it is important to understand that many lesions described in studies of Crohn's disease are not specific and cannot be distinguished from lesions seen in patients treated with NSAIDs. The presence of more than 3 ulcerations, in the absence of NSAID ingestion, constitutes the most commonly used diagnostic criterion for Crohn's disease.

Radiology of the small bowel – Which test?

Christian Stroszczynski

Radiology, University Hospital of Regensburg, Germany

Magnetic resonance imaging (MRI), Multislice-CT (MS-CT) and Ultrasound (US) are playing an increasing role in the evaluation of small-bowel disorders. Because of a growing awareness of the risks of ionizing radiation exposure, MRI has become popular for small bowel imaging.

Advantages of MRI include the ability to provide dynamic information regarding bowel distention and motility, ideal soft-tissue contrast, and a more or less safe intravenous contrast agent profile. When compared to MS-CT, limitations of MR imaging include the higher cost, the limited access to the scanner, a higher variability in examination quality, and lower resolution compared with those of MS-CT. MRI of the small bowel is indicated for patients with chronic inflammatory bowel disease, those for whom exposure to radiation is a concern, those with contraindications to MS-CT, and those with low-grade small-bowel obstruction.

Despite of all advances in MRI technique, MS-CT has its role for small bowel imaging because of the volumetric and multiplanar images that are now possible. MS-CT is an useful tool for the evaluation of the small bowel luminal contents, as well as the bowel wall, mesentery, and associated vasculature.

Ultrasound especially when contrast media becomes more and more useful in patients with chronic bowel diseases. When high resolution linear transducer were used, mural perfusion changes in active Crohn's disease can be appreciated. This technique could be an effective dynamic imaging modality for diagnosis and especially monitoring anti-inflammatory treatment.

Session II

Special topic enteroscopy

Technical overview: Balloons, spiral and beyond

Andrea May, [Christian Ell](#)

Innere Medizin II, HSK Dr. Horst Schmidt Klinik, Wiesbaden

Nowadays, five non-surgical flexible endoscopy techniques are available for small bowel endoscopy: push enteroscopy (PE), balloon-assisted enteroscopy using two balloons (double balloon enteroscopy, DBE) or one balloon (single balloon enteroscopy, SBE), balloon-guided enteroscopy (BGE) and spiral enteroscopy (SE).

Push enteroscopy is a cost-saving, easy and fast procedure for examination of the proximal jejunum, but for deeper small endoscopy the other flexible enteroscopy techniques are required. **BGE** plays not a considerable role in deep small bowel endoscopy because of limited insertion depth, mainly caused by the balloon guidance of this device. In contrast, the other flexible enteroscopy techniques are performed under scope guidance and are following either the push-and-pull principle (DBE, SBE) or the rotation principle (spiral). **Double balloon enteroscopy** is the “oldest” flexible enteroscopy technique and has become established throughout the world for diagnostic and therapeutic examinations of the small bowel, and is now used universally in clinical routine work. With a proper patient’s selection a high diagnostic yield of around 70–80% going along with a high therapeutic yield and an acceptable complication rate of approximately 1%. The published prospective trials comparing DBE and SBE clearly showed, that DBE is superior to SBE, at least regarding the rate of complete enteroscopy. Therefore, DBE still must continue to be regarded as the non-surgical gold standard procedure for deep small-bowel endoscopy at present, because it provides the highest rates of complete enteroscopy, which becomes increasingly useful. The recently introduced technique of **spiral enteroscopy** represents a promising method, because it can substantially reduce investigation time. But it still needs technical improvement, because the success of the anal route is still uncertain and therefore only a very low complete enteroscopy can be achieved. Additionally, retrospective data indicate, that spiral enteroscopy might be associated with a higher severe complication rate, at least in elderly patients. Larger prospective studies on spiral enteroscopy, and above all prospective studies comparing the three systems (DBE, SBE, SE), will have to be awaited before conclusive assessments can be made.

Algorithms for the investigation of intestinal diseases with capsule endoscopy and double balloon enteroscopy

M.M. Delvaux, G. Gay

Department of Internal Medicine and Digestive Pathology, Hôpitaux de Brabois, CHU de Nancy, Vandœuvre-lès-Nancy, France

The approach to intestinal diseases has dramatically changed over the last decade with the use of capsule endoscopy and double balloon enteroscopy. Digestive bleeding may be acute or chronic, overt or occult. On the other hand, digestive bleeding is qualified as “obscure” (ODB) when upper and lower classical endoscopic investigations do not find the source of bleeding, which is then often located in the small bowel. Moreover, capsule endoscopy (VCE) and double balloon enteroscopy (DBE) have been used in patients with suspicion of Crohn’s disease and other conditions, allowing a complete investigation of the small bowel.

The high diagnostic yield of VCE has been well demonstrated in patients with obscure digestive bleeding or with suspicion of Crohn’s disease. In these indications, it was constantly shown to be superior to that of any other classical endoscopic or radiological modality. On the other hand, DBE was shown as effective as capsule endoscopy in these indications.

Based on this background and taking into account the clinical picture of the patient, different situations can be discussed.

A. The patient with a unique, overt and acute bleeding, normal OGD and colonoscopy.

In this case, VCE may detect an intestinal source of bleeding, which will be further investigated by DBE, with a possibility of treating it. A particular situation should be considered in the presence of a young patient with abdominal pain and rectal bleeding, which is highly suggesting a “mid-intestinal” origin of the bleeding and could indicate a first line DBE to diagnose a Meckel’s diverticulum.

B. The patient with a recurrent overt bleeding.

Several classical endoscopic investigations, i.e. OGD and colonoscopy, have been performed and were normal. VCE should be undertaken rapidly, during the period of active bleeding and DBE decided in view of its results. However, when these investigations are performed quite a while after the bleeding episode, the diagnostic yield dramatically decreases, down to less than 10% of positive outcomes. In patients admitted with an active gastrointestinal bleeding and normal gastroscopy and colonoscopy, DBE could be used as first line examination, as it allows the diagnosis and the treatment of the bleeding lesion during a unique procedure.

C. The patient with a chronic, occult digestive bleeding and/or chronic iron-deficiency anaemia.

A CT-scanner should be performed first in the presence of clinical signs suggesting an intestinal obstruction. If the CT-scanner confirms the suspicion of an intestinal stenosis, DBE can be undertaken for both diagnostic and therapeutic purposes, e.g. removal of an ulcerated polyp, dilation of a stenosis, decompression of an intestinal

intussusception. By contrast, in the absence of an intestinal stenosis, VCE appears to be very effective in patients with occult ODB and/or chronic iron-deficiency anaemia. If the VCE is negative, a DBE will not be proposed because the high (close to 100%) negative predictive value of CE, while in the case of a positive finding, VCE may direct the route of insertion of the endoscope for the DBE, avoiding double procedures.

D. Patients with suspicion of Crohn's disease.

Patients with a suspicion of Crohn's disease are defined by the presence of clinical and/or biological signs suggesting Crohn's disease and normal ileo-colonoscopy. In these patients, VCE may detect intestinal ulcerations suggesting Crohn's disease. However intestinal stenoses are frequent in patients with Crohn's disease and the risk of blockade of the capsule has to be carefully assessed before undertaking a VCE procedure. As VCE is less invasive than DBE, it should be proposed first when possible. DBE can be used secondarily to obtain biopsies or dilate a stenosis.

E. Particular situations.

DBE should be used first in patients with surgically modified anatomy, in particular in the presence of an anastomosis with an afferent and an efferent intestinal loops. Indeed, the afferent will likely not be explored by VCE, not be opacified during radiological investigations and difficult to catheterize during endoscopy. By contrast, DBE is effective to investigate patients with surgical anastomoses, including patients with a *Blind loop syndrome*.

In most cases, DBE should be undertaken after the VCE in the absence of obstructive signs. By contrast, DBE should be undertaken first in patients with surgically modified anatomy, especially those with a difficult to access intestinal afferent loop as well as in young patients with rectal bleeding and abdominal pain to diagnose a Meckel's diverticulum. Advances made with VCE and DBE have dramatically decreased the role of intra-operative enteroscopy in patients with ODB.

Therapeutic enteroscopy

Klaus Mönkemüller^{1,2}

¹Department of Internal Medicine, Gastroenterology and Infectious Diseases, Marienhospital, Bottrop

²Division of Gastroenterology, Hepatology and Infectious Diseases, Otto-von-Guericke University, Magdeburg, Germany

Although enteroscopy has been performed for decades it was not until the introduction of double balloon enteroscopy in the year 2001 that we were really able to fully investigate the entire small bowel. A few years afterwards single balloon enteroscopy (SBE) was introduced. Nowadays we have a third method that allows deep small bowel enteroscopy: spiral enteroscopy (SE) (1–3). These enteroscopy methods have definitely increased our ability to visualize the small bowel. It is logical to deduce that the increased disease recognition was going to be followed by increased endoscopic therapeutic interventions (3–10). This makes DBE, SBE and SE especially useful when comparing it to non-invasive endoscopic methods such as capsule endoscopy as a direct therapeutic intervention can be accomplished.

The list of therapeutic interventions using enteroscopy includes 1) hemostasis for small bowel angiodysplasias, ulcers and Dieulafoy lesions using argon plasma coagulation, injection of epinephrine or glue and clip application; 2) polypectomy and endoscopic mucosal resection, especially in patients with Peutz-Jeghers and familial adenomatous polyposis syndromes; 3) dilation of strictures (e.g. Crohn's disease); 4) foreign body retrieval (capsules, needles, coins, etc); 5) placement of small bowel stents; 6) percutaneous gastrostomy tube placement in patients with gastric bypass, and 7) therapy of the pancreatobiliary system in patients with surgically altered proximal intestinal anatomy (3–8).

In this meeting we will define therapeutic small bowel endoscopy, exemplify each of the potential interventions, discuss the advantages, disadvantages, risks and benefits of various therapeutic small bowel interventions, describe the available equipment and utensils and discuss the future of therapeutic small bowel endoscopy.

References:

1. Mönkemüller K, Weigt J, Treiber G et al. Diagnostic and therapeutic impact of double-balloon enteroscopy. *Endoscopy*. 2006; 38: 67–72.
2. Mönkemüller K, Bellutti M, Fry LC, Malfertheiner P. Enteroscopy. *Best Pract Res Clin Gastroenterol*. 2008; 22 (5): 789–811.
3. Mönkemüller K, Neumann H, Meyer F, Kuhn R, Malfertheiner P, Fry LC. A retrospective analysis of emergency double-balloon enteroscopy for small-bowel bleeding. *Endoscopy*. 2009; 41: 715–717.

4. Kuno A, Yamamoto H, Kita H, et al. Double-balloon enteroscopy through a Roux-en-Y anastomosis for EMR of an early carcinoma in the afferent duodenal limb. *Gastrointest Endosc.* 2004; 60: 1032–1034.
5. Sakai P, Kuga R, Saftle-Ribeiro AV, et al. Is it feasible to reach the bypassed stomach after roux-en-Y gastric bypass for morbid obesity? The use of the double balloon enteroscope. *Endoscopy.* 2005; 37: 566–569.
6. Ross AS, Semrad C, Waxman I, Dye C. Enteral stent placement by double balloon enteroscopy for palliation of malignant small bowel obstruction. *Gastrointest Endosc.* 2006; 64: 835–837.
7. Despott EJ, Gabe S, Tripoli E, Konieczko K, Fraser C. Enteral access by double-balloon enteroscopy: An alternative method of direct percutaneous endoscopic jejunostomy placement. *Dig Dis Sci.* 2010 Jun 29. [Epub ahead of print].
8. Neumann H, Fry LC, Rickes S, Jurczok C, Malfertheiner P, Mönkemüller K. A 'double-balloon enteroscopy worth the money': endoscopic removal of a coin lodged in the small bowel. *Dig Dis.* 2008; 26: 388–389.
9. Mönkemüller K, Zabielski M, Poppen D, Fry LC. Endoscopic removal of an impacted root canal needle in the jejunum using double-balloon enteroscopy. *Gastrointest Endosc.* 2010 Nov 11. [Epub ahead of print].
10. Mönkemüller K, Fry LC, Bellutti M, Neumann H, Malfertheiner P. ERCP with the double balloon enteroscope in patients with Roux-en-Y anastomosis. *Surg Endosc.* 2009; 23: 1961–1967.

Address for correspondence:

Prof. Klaus Mönkemüller, M.D., Ph.D., FASGE
Department of Internal Medicine
Gastroenterology and Infectious Diseases
Marienhospital Bottrop
Josef-Albers-Str. 70
46236 Bottrop
Germany
Telephone: +49 391 6713100
Telefax: + 49 391 6713105
E-mail: moenkemueller@yahoo.com

Session III

Diagnosis and assessment of IBD

Endoscopic surveillance in IBD: Who needs what and when?

D.C. Baumgart, M.D., Ph.D.

Division of Gastroenterology and Hepatology, Department of Medicine, Charité Medical Center - Virchow Hospital, Medical School of the Humboldt, University of Berlin, Germany

Patients with longstanding inflammatory bowel disease (IBD) are at risk of developing a variety of complications. Among those, malignant complications include colon cancer in patients with ulcerative or Crohn's colitis, particularly in the presence of extensive colitis or primary sclerosing cholangitis, as well as atypical small bowel adenocarcinoma in patients with Crohn's enteritis. These epidemiologic data and the fact that cancers diagnosed at an earlier stage generally have a better prognosis have led to the implementation of screening and surveillance colonoscopy in IBD patients as a standard of care in most Western countries, endorsed by major professional societies and expert groups in consensus conferences.

Good judgment based on experience can save lives, patients' lives that is. There is evidence that non-IBD patients with a negative colonoscopy have a reduced incidence of colorectal cancer over a 10 year period. This favorable outcome largely depends on the quality of the endoscopy performed. The quality of colonoscopy as a screening tool for colorectal cancer has recently come under scrutiny. Some important factors affecting the quality of a colonoscopy include proper bowel preparation, complete, careful inspection of the entire colon, which require a minimum withdrawal time and adherence to recommended management guidelines of various professional societies.

Since there is no lack of guidelines, we need to improve their adoption and application in clinical practice. Moreover, IBD experts should be encouraged to share their experience and expertise beyond publications and presentations at national and international meetings. At Charité, where we operate one of the largest comprehensive inflammatory bowel disease centers in Germany, our patients are followed by their private gastroenterologists and us together. General gastroenterologists in private practice and colleagues at local or regional in community hospitals usually refer their patients, when the diagnosis is suspected, the management becomes complex or the patient desires so. Our task is to assist them in establishing the diagnosis or the management, but not replace their role. Many patients receive their screening and surveillance endoscopies at our center. In addition, we have implemented a clinical hands-on rounds program, where clinicians have the opportunity to receive advanced endoscopy instruction on specifically selected and scheduled cases, join us in clinic to update their knowledge on current management of IBD, or participate in regular conferences to discuss cases from their own practice with academic IBD experts.

In summary, the science of medicine can only successfully be translated into the art of medicine, if we as academicians and specialists, ensure the wide distribution and adoption of the clinical implications of our research to enable quality care everywhere.

Address for correspondence:

Prof. Daniel C. Baumgart, M.D., Ph.D.
Division of Gastroenterology and Hepatology
Department of Medicine
Charité Medical Center – Virchow Hospital
Medical School of the Humboldt – University of Berlin
13344 Berlin
Germany
Telephone: +49 30 450 553315
Telefax: +49 30 450 553983
E-Mail: daniel.baumgart@charite.de
Website: <http://www.entzündungszentrum.de>

Colonoscopic surveillance: State of the art – Reduction of biopsies

Martin Götz

I. Medizinische Klinik und Poliklinik, Universitätsmedizin der Johannes Gutenberg-Universität Mainz, Germany

Long-standing ulcerative colitis (UC) and colitis in Crohn's Diseases (CD) are associated with an increased risk to develop intraepithelial neoplasia (IN). Lesions may gradually progress from inflammation and low grade (IN) to high grade IN and even cancer. This time for this progression offers a window of opportunity to detect precursor lesions of colitis-associated cancers. White light endoscopy (WLE) with 40 to 50 random biopsies is accepted standard of care in the surveillance of these patients. However, IN in UC are commonly flat and multifocal, therefore WLE may miss a significant proportion of these lesions (Rutter MD et al., *Gastrointest Endosc* 2004; Rubin DT et al., *Gastrointest Endosc* 2007). In addition, the yield of random biopsies to detect IN is low, and random biopsies are expensive, labor-intensive and distract from scrutinizing the colon.

Chromoendoscopy enhances the contrast between normal and pathologic mucosa by spraying of intravital dyes such as methylene blue or indigo carmine. Lesions are characterized based on a simplified Kudo's pit pattern classification. Multiple randomized trials have demonstrated that chromoendoscopy increases the lesion detection rate 3- to 5-fold in comparison to WLE. In addition, random biopsies of apparently normal mucosa were of no additional value. Therefore, chromoendoscopy with targeted biopsies of suspicious lesions only has been incorporated into recent European and US surveillance guidelines for appropriately trained endoscopists.

Chromoendoscopy however relies on the physical application of dyes. Virtual chromoendoscopy techniques with rotating filters (Narrow Band Imaging [NBI], Olympus) or post image acquisition algorithms (Fujinon Intelligent Contrast Enhancement [FICE, Fuji] or I-scan [Pentax]) carry the potential to provide contrast enhancement without spraying colour onto the mucosa. However, no trial with virtual chromoendoscopy techniques has shown enhanced detection of IN compared to WLE so far. This may have several reasons: In most systems, the luminal illumination with virtual chromoendoscopy is slightly inferior when compared with WLE, limiting the field of view. On the other hand, most new endoscopes come with high definition that per se may go along with enhanced detection of IN, potentially overruling the advantage of using virtual chromoscopy. In addition, in contrast to sporadic adenomas, IN in IBD usually follow an inflammation – neoplasia sequence. That means that most IN arise in regions of (former) inflammation with altered vascular patterns. These vascular patterns are augmented by virtual chromoendoscopy techniques (in contrast to chromoendoscopy which augments the pit pattern), therefore the differentiation of inflammation vs. IN may be difficult.

Autofluorescence imaging (AFI) has the potential to serve as a red flag technique for macroscopic detection of IN, and first trials have indicated better detection of IN by AFI. Since AFI suffers from limited specificity to differentiate between inflammation from IN, NBI has been successfully used to characterize lesions during ongoing endoscopy (trimodal imaging) and overcome the low specificity of AFI.

Confocal laser endomicroscopy (CLE) takes a different approach in that it does not only predict histology from pit or vascular patterns, but actually provides in vivo microscopy of colonic lesions at cellular level. Two systems are currently available, an endoscope based scanner and a probe-based system. In a first study with endoscope-based CLE, the accuracy for prediction of neoplasia was 98% using a simple classification. Normal mucosa in optical biopsies could be predicted with an accuracy of 99%, thus abrogating the need for real random biopsies in this study.

All these approaches aim at overcoming shortcomings of WLE in a move towards abandoning untargeted random biopsies for targeted, “smart” biopsies. Future efforts to optimize endoscopic surveillance in inflammatory colitis should aim at identifying patients at high risk to develop IN, tailor individual surveillance intervals, use red flag techniques for IN detection and may even predict response to tailored therapy.

Address for correspondence:

PD Dr. Martin Götz
I. Medizinische Klinik und Poliklinik
Universitätsmedizin der Johannes Gutenberg-Universität Mainz
Langenbeckstr. 1
55131 Mainz
Germany
E-Mail: mgoetz@mail.uni-mainz.de

PSC – Diagnostic and therapeutic problems

P. Sauer

Medizinische Universitätsklinik, Interdisziplinäres Endoskopie-Zentrum, Heidelberg, Germany

Primary sclerosing cholangitis (PSC) is a chronic progressive cholestatic disorder that is characterized by inflammation, fibrosis, and strictures of medium size and large ducts in the intrahepatic and extrahepatic biliary tree. Progressive destruction of bile ducts leads to end-stage liver disease and portal hypertension and liver failure. PSC is associated with numerous complications including cholestasis and associated problems, development of dominant strictures, cholelithiasis and cholangitis, cholangiocarcinoma, and colon cancer.

The diagnosis of PSC is established by the demonstration of characteristic multifocal stricturing and dilation of intrahepatic and/or extrahepatic bile ducts on cholangiography. Ultrasound may be altered but findings are usually not diagnostic. Magnetic resonance cholangiography may be an alternative to endoscopic cholangiography, but to support therapeutic decisions the image quality has to be further improved. Cholangiography may be normal or shows only marginal unspecific alterations in early stage disease or in a small percentage of patients who have a variant of PSC described as "small-duct primary sclerosing cholangitis." Secondary causes of the cholangiographic findings including chronic bacterial cholangitis, infectious or ischemic cholangiopathy, and malignancy should be excluded.

Up to 60% of patients with PSC develop a dominant stricture in the intrahepatic or extrahepatic biliary tree. The definition of a dominant stricture is a stenosis with a diameter of ≤ 1.5 mm in the common bile duct or ≤ 1 mm in the hepatic ducts. Patients may present with evidence of mechanical biliary obstruction manifested by jaundice, pruritus, and ascending cholangitis, but symptoms are not consistent. The cholangiographic finding and the clinical presentation is difficult to distinguish from that of cholangiocarcinoma, even with combined imaging, endoscopic biopsy, and cytology. This problem is supported by the observation that up to 10% of patients with PSC undergoing liver transplantation had an unsuspected cholangiocarcinoma. The medical, endoscopic, and surgical therapies are aimed to slow progression of the disease. A variety of immunosuppressive and anti-inflammatory agents have been studied in patients with PSC but none has shown a consistent benefit on overall or transplant-free survival. The subset of patients with PSC and a dominant extrahepatic biliary stricture seems to profit from endoscopic therapy. Whether treatment of a dominant stricture improves outcomes has not been evaluated in controlled trials. But a number of reports have documented clinical and radiographic improvement in such patients following endoscopic dilation with or without placement of a biliary stent. An important potential clinical benefit is relief of jaundice and pruritus. Therapeutic biliary endoscopy in such patients should be performed at centers with adequate experience. Antibiotics should be given since patients with PSC are at increased risk for the development of cholangitis following biliary tract intervention.

Address for correspondence:

PD Dr. Peter Sauer
Medizinische Universitätsklinik
Interdisziplinäres Endoskopie-Zentrum
Im Neuenheimer Feld 410
69120 Heidelberg
Germany
E-Mail: peter.sauer@med.uni-heidelberg.de

Session IV

Technicalities of colonoscopy

Endoscopic microscopy – Where are we heading?

R. Bisschops

Department of Gastroenterology, KU Leuven, Belgium

Confocal laser endomicroscopy (CLE) has recently entered the field of advanced endoscopic imaging, enabling on site histology during ongoing endoscopy. Basically, three different patterns can be seen in the colon: normal, neoplastic and inflammatory mucosa. After IV fluorescein injection, normal mucosa is shown as a regular pattern of colonic crypts with typical mucin containing goblet cells and with a relative constant intercryptal and crypt diameter. Deeper scanning reveals normal blood vessels surrounding the crypts in a honeycomb like pattern. In contrast, neoplastic changes are characterized by loss of goblet cells and crowding of irregular tubular architecture and loss of cellular junctions. Inflammatory changes present as crypt destruction, increased intercryptal distance and variable size of the crypts.

What could be the future indications of CLE?

1) Differentiating neoplastic from inflammatory changes constitutes a promising diagnostic tool in screening for dysplasia in ulcerative colitis (UC). This can help to further increase the efficacy of chromo-endoscopy in dysplasia detection and reduce the number of biopsies needed. In addition, the possibility to differentiate ALM from DALM could have an immediate impact on patient management.

2) The diagnosis of collagenous colitis depends on multiple random biopsies to detect the patchy distributed microscopic changes of this condition. Case series have shown that CLE can guide the endoscopist to take more representative biopsies to make the diagnosis. Large prospective trials are needed to confirm this finding.

3) An interesting clinical application is graft versus host disease (GVHD). A pilot study showed that it was possible to predict the presence of GVHD in 14/19 patients with GVHD out of 35 patients that were referred for diarrhea after stem cell transplantation.

4) CLE for standard polyp surveillance is probably redundant. Small polyps in the rectosigmoid and with hyperplastic appearance can be discarded. However, polyps of more than 1 cm or located in the right side, need to be resected. CLE is unlikely to change this treatment paradigm, especially because it can currently not differentiate between classical hyperplastic and sessile serrated adenomas.

5) Future additional technological improvements of the system with faster Z-scanning, deeper light penetration and 3D reconstruction will help to improve the quality of CLE. Reports on in vivo molecular imaging provide a promising glance at the future possibilities of CLE imaging.

In conclusion, correlation between CLE and classical histology from biopsies is very good for differentiating normal mucosa from neoplastic and inflammatory changes. In the colon, screening for dysplasia in UC, chronic diarrhea or suspicion of GVHD are currently the most promising clinical indications. Further technological development carry the potential to bring CLE even closer classical histology.

Session V

Colon cancer screening

Colonoscopy screening: Status in Europe

J.F. Riemann

Chairman, LebensBlicke Foundation for the Prevention of Colorectal Cancer
Klinikum der Stadt Ludwigshafen, Germany

Colorectal cancer (CRC) is the second leading cancer in Europe. Every 25th of the European population will develop colorectal cancer during his life. Approximately 435.000 cancers are newly diagnosed in Europe. Round about 50% will die making CRC the second leading cause of cancer death in Europe (1).

Incidence and mortality rates from colorectal cancer vary substantially throughout Europe with Hungary having the highest mortality rate and Cyprus having the lowest. It goes without saying that lifestyle, modality of screening procedures and of course different diagnostic and therapeutic strategies play an important role to explain these differences (2). Randomized trials in people of average risk invited to attend screening have shown a substantial reduction in CRC mortality (3, 4).

In 2003 the Ministers of Health of the European Union have accepted a recommendation for cancer screening based on a survey among 22 of the 27 countries (82%). This survey was completed by information derived from 2 European projects which were supported by a European action programme in the framework of public health: The European Cancer Network (ECN) and the European Cancer Information Network (EUNICE).

Recommendations for colorectal cancer screening are based on the fact that colorectal cancer is especially suitable for screening. One of the major preconditions is the so-called adenoma carcinoma sequence, which covers a period of 10–15 years before cancer develops with polypectomy being the most important step to reduce colorectal cancer burden (5). More advanced lesions tend to bleed on an occult basis from time to time therefore making FOBT a simple, but successful screening test however with limitations.

At that time in 2003 only in a very few countries like Germany a nationwide screening programme was introduced. In the majority of the European countries FOBT-programmes were at least offered regionally.

On the basis of the networks it was soon be clear that there must be a change in handling colorectal cancer screening in Europe. Therefore, initiatives of the European Parliament in 2004, 2006 and 2008 supported the efforts to introduce population-based colorectal cancer screening programmes in the European Union (6). By the end of 2007 indeed several European countries were in the process of implementing a national population screening programme (7). They started in 5 countries nation wide (Finland, France, Italy, Poland, United Kingdom). 7 countries had already established nation wide but not population-based screening programmes (Austria, Bulgaria, Czech Republic, Germany, Greece, Latvia and the Slovak Republic). Further 5 countries were planning or piloting a nation wide population-based programme (Hungary, Cyprus, Portugal, Romania and Slovenia) (Fig. 1). In these 17 countries the majority used only FOBT, in 6 countries the combination of FOBT and endoscopy and 1 only colonoscopy. In the meantime, 10 member states

improved their status of CRC screening programmes (Czech Republic, France, Ireland, Lithuania, Portugal, Slovak Republic, Slovenia, Spain, Sweden and the United Kingdom). FOBT at this time is the only recommendation in regard to the European screening policy due to the excellent evidence based results on the basis of large prospective randomized trials (4, 14). Mass screening using FOBT followed by colonoscopy if the test is positive is very encouraging (8).

Distribution of Colorectal Cancer Screening Programmes based on the Faecal occult Blood Test in the EU in 2007

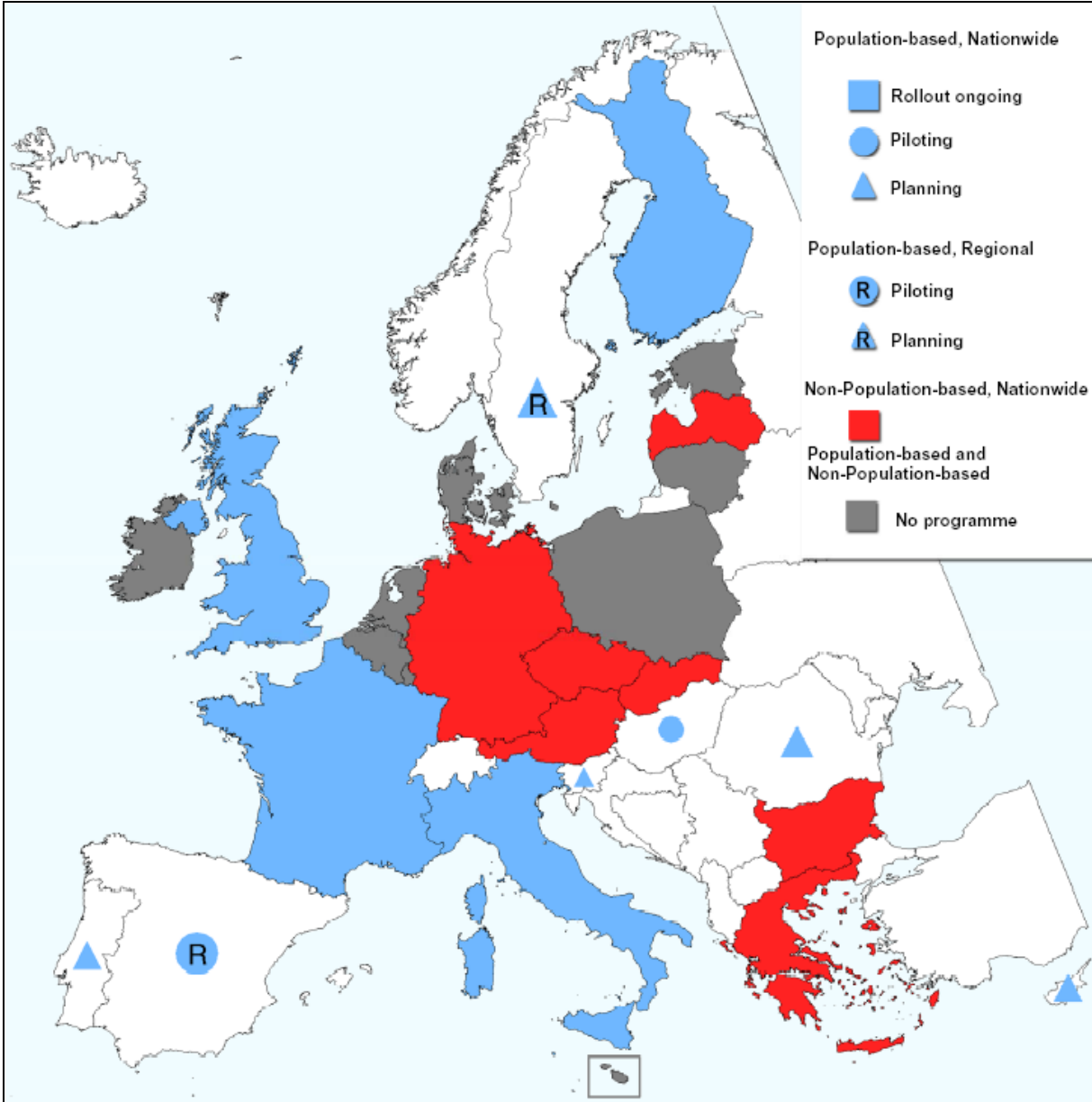


Figure 1: Colorectal cancer screening programmes based on FOBT (faecal occult blood test) in the European Union in 2007, by programme type (population-based; non-population-based; no programme) and country implementation status (population-based: nationwide or regional, rollout complete or ongoing, piloting and/or planning; non-population-based: nationwide or regional). Programmes shown use screening test recommended by the Council of the European Union in 2003. Source: ECN9, KOM(2008)882 final

In contrast to the FOBT, there are up to now no randomized controlled trials (RCT) investigating the efficacy of colonoscopy screening. However, there is a multicentre trial on the way which covers Norway, Poland, Iceland, Sweden, Latvia and the Netherlands. This is the first trial which compares a once colonoscopy to no screening. There are only observational studies, cohort studies or cross-sectional surveys which demonstrate that colonoscopy is more sensitive than sigmoidoscopy in detecting adenomas and cancers (9) and may reduce cancer mortality up to 65% in individuals screened (10).

In order to overcome progression of cancer in Europe including the colorectal cancer, the European Commission proposes a European partnership for action against cancer for the period of 2009 to 2013 to support the member states in their efforts to tackle cancer by providing a framework for identifying and sharing information, capacity and expertise in cancer prevention and control (11). One of the major goals is it's early detection. Based on the ongoing experiences FOBT will be the standard recommendation in Europe due to the different financial possibilities in European countries. Colonoscopy is not a screening test recommended by the EU, however colonoscopy plays a key role in every colorectal cancer screening programme because it is the gold standard by which the status of people with positive screening tests is evaluated. The same applies to patients in a symptomatic service (11).

It seems clear that a population-based screening should be introduced in Europe because some studies have shown that the personal invitation encouraged and supported by the regional physician is the best way to motivate and to convince people to go to screening (12). Concerning endoscopy based programmes Poland is the leading country which has introduced a population-based nationwide colonoscopy screening (13); Italy is planning a programme based on flexible sigmoidoscopy. In contrast, in Germany, Austria, Czech Republic, Slovakia and Greece, there is a non-population based screening programme which, however, is also nationwide.

One of the preconditions for introducing endoscopy based programmes is the necessity to introduce quality insurance programmes for all who participate in these programmes: endoscopist, pathologist, nurses, other staff members. The European Society of Gastrointestinal Endoscopy has developed a quality programme which covers these major aspects.

In conclusion: Looking throughout Europe, there is a big improvement in population based screening programmes for colorectal cancer; however, in regard to colonoscopy, a lot of work remains to do especially to compare the national screening programmes and to draw the right conclusions for the EU (15).

References:

1. Ferlay J, Parkin DM, Steliarova-Foucher E. Estimates of cancer incidence and mortality in Europe in 2008. *Eur J Cancer*. 2010; 46: 765–781.
2. Von Karsa L., Lignini T. A., Patnick J., Lambert R., Sauvaget C. The dimensions of CRC problem. *Best Pract Res Clin Gastroenterol*. 2010; 24: 381–396.
3. Atkin WS, Edwards R, Kralj-Hans, Wooldrage K., Hart AR, Northover JM, Parkin DM, Wardle J, Duffy SW, Cuzick J. Once-only flexible sigmoidoscopy screening in prevention of colorectal cancer: a multicentre randomized controlled trial. *Lancet*. 2010; 375: 1624–1633.
4. Mandel JS, Church TR, Bond JH, Ederer F, Geisser MS, Mongin SJ, Snover DC, Schuman LM. The effect of fecal occult-blood screening on the incidence of colorectal cancer. *N Engl J Med*. 2000; 343: 1603–1607.
5. Winawer SJ, Zauber AG, Ho MN, O'Brien MJ, Gottlieb LS, Sternberg SS, Schapiro M, Bond JH, Panish JF. Prevention of colorectal cancer by colonoscopic polypectomy. The National Polyp Study Workgroup. *N Engl J Med*. 1993; 329: 1977–1981.
6. Commission of the European Communities (2008), Report from the Commission to the Council, the European Parliament, the European Economic and Social Committee and the Committee of the Regions – Implementation of the Council Recommendation of 2 December 2003 and Cancer screening (2003/878/EC) Russels Report no. COM (2008) 882 final.
7. Von Karsa I, Anttila A, Ronco G, Ponti A, Malila N, Arbyn N, Segnan N, Castillo-Beltran M, Boniol M, Ferlay J, Hery C, Sauvaget C, Voti L, Autier P. Cancer Screening in the European Union. Report on the implementation of the Council Recommendation on Cancer Screening – First Report European Commission, Luxembourg 2008.
8. Manfredi S, Piette C., Durand G, Plihon G, Mallard G, Bretagne JF. Colonoscopy results of a French regional FOBT-based colorectal cancer screening program with high compliance. *Endoscopy*. 2008; 40: 422–427.
9. Walsh JM, Terdiman JP. Colorectal cancer screening: Scientific review. *JAMA*. 2003; 289: 1288–1296.
10. Kahi CJ, Imperiale TF, Juliar BE, Rex DK. Effect of screening colonoscopy on colorectal cancer incidence and mortality. *Clin Gastroenterol Hepatol*. 2009; 7: 770–775.
11. European guidelines for quality assurance in colorectal cancer screening and diagnosis - First edition, Lyon 2010.

12. Brenner H, Hoffmeister M, Arndt V, Stegmaier C, Altenhofen L, Haug U. Protection from right- and left-sided colorectal neoplasms after colonoscopy: Population-based study. *J Natl Cancer Inst.* 2010; 102: 89–95.
13. Regula J, Rupinski M, Krasewska E, Polkowski M, Pachlewski J, Orłowska J, Nowacki MP, Butruk E. Colonoscopy in colorectal cancer screening for detection of advanced neoplasia. *N Engl J Med.* 2006; 355: 1863–1872.
14. Lindholm E, Brevinge H, Haglund E. Survival benefit in a randomized clinical trial of faecal occult blood screening for colorectal cancer. *Brit J Surg.* 2008; 95: 1029–1036.
15. Fischbach W. Nationale Darmkrebs-Vorsorgeprogramme in Europa. *MMW Fortschr Med.* 2009; 151: 27–33.

Which non-invasive filter tests?

Christian Pox

Medizinische Klinik, Ruhr-Universität Bochum, Germany

The following non-invasive stool tests for colorectal cancer (CRC) screening exist:

- Faecal occult blood testing (FOBT)
 - o Guaiac or immunochemical
- Genetic stool tests
- M2-PK

Filter tests detect blood in the stool (Faecal occult blood tests (FOBT)) relying on the fact that colorectal neoplasms tend to bleed more often than normal mucosa. Currently the most widely used tests are guaiac-based (gFOBT). If blood is present in the stool the haemoglobin with its pseudoperoxidase activity will result in a blue colour change of the test field in the presence of hydrogen peroxide. Because colorectal neoplasms tend to bleed intermittently testing several stool samples increases the yield. It has become standard to test three consecutive stools i.e. using three test slides for screening purposes. A test is positive if one or more of the six test fields turn blue. A positive test has to be followed up by complete colonoscopy. Several randomised controlled trials have shown that gFOBT are able to achieve a reduction in CRC-related mortality. A meta-analysis concluded that a one-time test is able to reduce CRC-related mortality by 25%. This reduction is achieved by detecting asymptomatic cancers at an early stage with a better prognosis. However gFOBT have a low sensitivity for colorectal adenomas and are thus unlikely to be able to reduce the incidence of CRC. Furthermore gFOBT are not specific for human blood and can be influenced by external factors.

Immunochemical tests (iFOBT) only detect human blood in the stool. In two recent randomised studies from the Netherlands comparing guaiac and immunochemical tests in the asymptomatic population iFOBT were found to detect more cancers than gFOBT. Furthermore iFOBT were able to detect more advanced adenomas thus having the potential to be able to reduce the incidence of CRC as well as CRC-related mortality.

In the recently released European CRC screening guidelines iFOBT are considered the screening test of choice. However several questions remain. In one study comparing different iFOBT available in Germany sensitivity and specificity varied widely. It is currently unknown what the optimal cut-off value for an iFOBT to be considered positive should be and what the number of stool samples is that are required.

Genetic stool tests detect mutations in stool that can be found in CRC. The original test testing for 21 genetic changes was found to be superior to gFOBT for the detection of cancers. However the sensitivity was moderate (51.6%) and the sensitivity for advanced adenomas was low. In the meantime the test has been modified improving DNA-extraction and reducing the number of mutations tested for as well as including a methylation marker. The efficacy of the modified test in the screening population is unknown.

M2-PK is an isomer of the enzyme pyruvate kinase that is involved in glycolysis. Studies have found a good sensitivity for cancers, a low sensitivity for advanced adenomas with a specificity of around 80%.

Address for correspondence:

Dr. C. Pox
Medizinische Klinik
Ruhr-Universität Bochum
Knappschaftskrankenhaus
In der Schornau 23–25
D-44892 Bochum
Germany
E-Mail: christian.p.pox@ruhr-uni-bochum.de

List of Chairpersons, Speakers and Scientific Organizers

Dr. A. Adler

Hepatology/Gastroenterology
Charité – Universitätsmedizin
Campus Virchow-Klinikum (CVK)
Augustenburger Platz 1
13353 Berlin
Germany

Prof. Dr. D.C. Baumgart

Medizinische Klinik mit Schwerpunkt
Gastroenterologie und Hepatologie
Charité – Universitätsmedizin
Campus Virchow-Klinikum (CVK)
Augustenburger Platz 1
13353 Berlin
Germany

U. Beilenhoff

Ferdinand-Sauerbruch-Weg 16
89075 Ulm
Germany

Prof. Dr. R. Bisschops

University Ziekenhuis
Gasthuisberg
Gastro-entérologie
Herestraat 49
3000 Leuven
Belgium

Dr. C. Bojarski

Gastroenterologie
Charité – Universitätsmedizin
Campus Benjamin Franklin (CBF)
Hindenburgdamm 30
12203 Berlin
Germany

Dr. B. Bokemeyer

Gastroenterologe
Uferstr. 3
32423 Minden
Germany

Prof. Dr. G. Costamagna

Policlinico Gemelli
Unità Operativa di
Endoscopia Digestiva
Largo A. Gemelli, 8
00168 Roma
Italy

Dr. M.M. Delvaux

Hôpitaux de Brabois
C.H.U. de Nancy
Department of Internal Medicine
& Digestive Pathology
Allée du Morvan
54511 Vandœuvre-lès-Nancy
France

Prof. Dr. J. Devière

Université Libre de Bruxelles
Hôpital Erasme
Gastro-entérologie
Route de Lennik 808
1070 Bruxelles
Belgium

Dr. R. Drossel

Internist
Gastroenterologe
Etkar-André-Str. 8
12619 Berlin
Germany

Prof. Dr. C. Ell

Innere Medizin II
HSK Dr. Horst Schmidt Klinik
Ludwig-Erhard-Str. 102
65199 Wiesbaden
Germany

Prof. Dr. S. Faiss

Innere Medizin III
Asklepios Klinik Barmbek
Rübenkamp 220
22307 Hamburg
Germany

Prof. Dr. L. Familiari
Policlinico Universitario
Clinica Medica I
98100 Messina
Italy

Prof. Dr. K. Gellert
Chirurgie
Sana-Klinikum Lichtenberg
Oskar-Ziethen-Krankenhaus
Fanningerstr. 32
10365 Berlin
Germany

PD Dr. M. Götz
I. Medizinische Klinik und Poliklinik
Universitätsmedizin der
Johannes Gutenberg-Universität
Langenbeckstr. 1
55131 Mainz
Germany

Prof. Dr. F. Hagenmüller
Innere Medizin I
Asklepios Klinik Altona
Paul-Ehrlich-Str. 1
22763 Hamburg
Germany

PD Dr. D. Hartmann
Innere Medizin C
Klinikum der Stadt Ludwigshafen
Bremsenstr. 79
67063 Ludwigshafen
Germany

Prof. Dr. F. Hartmann
Innere Medizin
Katharina-Kasper-Kliniken
St. Marienkrankenhaus
Richard-Wagner-Str. 14
60318 Frankfurt
Germany

Prof. Dr. J. Hochberger
Innere Medizin III
St. Bernward-Krankenhaus
Treibeinstr. 9
31134 Hildesheim
Germany

T. Hrnjak
Interdisziplinäre Endoskopie
Charité – Universitätsmedizin
Campus Virchow-Klinikum (CVK)
Augustenburger Platz 1
13353 Berlin
Germany

Prof. Dr. M. Jung
Innere Medizin
Katholisches Klinikum Mainz
St. Hildegardis-Krankenhaus
Hildegardstr. 2
55131 Mainz
Germany

Dr. C. Jürgensen
Gastroenterologie/Hepatologie
Charité – Universitätsmedizin
Campus Charité Mitte
Schumannstr. 20–21
10117 Berlin
Germany

Dr. F. Kinzel
Innere Medizin
Immanuel Klinik Rüdersdorf
Seebad 82/83
15562 Rüdersdorf
Germany

Dr. P.N. Meier
Gastroenterologie
Diakoniekrankenhaus
Henriettenstiftung
Schwemannstr. 17
30559 Hannover
Germany

Prof. Dr. H. Messmann
Innere Medizin III
Klinikum Augsburg
Stenglinstr. 2
86156 Augsburg
Germany

Prof. Dr. K. Mönkemüller
Department of Internal Medicine
Marienhospital Bottrop
Josef-Albers-Str. 70
46236 Bottrop
Germany

Prof. Dr. J. Mössner
Medizinische Klinik und Poliklinik II
Universitätsklinikum Leipzig AöR
Liebigstr. 20
04103 Leipzig
Germany

Prof. Dr. S. Mutze
Radiologie
Sana-Klinikum Lichtenberg
Oskar-Ziethen-Krankenhaus
Fanningerstr. 32
10365 Berlin
Germany

Prof. Dr. P. Neuhaus
Allgemein- und Viszeralchirurgie
Charité – Universitätsmedizin
Campus Virchow-Klinikum (CVK)
Augustenburger Platz 1
13353 Berlin
Germany

Prof. Dr. G. Niedobitek
Pathologie
Sana-Klinikum Lichtenberg
Oskar-Ziethen-Krankenhaus
Fanningerstr. 32
10365 Berlin
Germany

Dr. G. Niemann
Innere Medizin II
Helios Klinikum Emil von Behring
Walterhöferstr. 11
14165 Berlin
Germany

U. Pfeifer
Endoskopieschwester
Evangelisches Krankenhaus
Kirchfeldstr. 40
40217 Düsseldorf
Germany

Prof. Dr. T. Ponchon
Hôpital Edouard Herriot
Specialités Digestives
Pavillon H
Place d'Arsonval
69437 Lyon
France

Dr. C. Pox
Medizinische Klinik
Ruhr-Universität Bochum
Knappschaftskrankenhaus
In der Schornau 23–25
44892 Bochum
Germany

Prof. Dr. J.F. Riemann
c/o Stiftung LebensBlicke
Klinikum der
Stadt Ludwigshafen
Bremerstr. 79
67063 Ludwigshafen
Germany

Prof. Dr. T. Rösch
Interdisziplinäre Endoskopie
Universitätsklinikum Eppendorf
Martinistr. 52
20251 Hamburg
Germany

Dr. E. Santo
Tel Aviv Medical Center
Ichilov Hospital
Department of Gastroenterology
and Liver Diseases
6, Weizman Street
64239 Tel Aviv
Israel

PD Dr. P. Sauer
Innere Medizin IV
Interdisziplinäres Endoskopie-Zentrum
Universitätsklinikum Heidelberg
Im Neuenheimer Feld 410
69120 Heidelberg
Germany

Dr. G. Schachschal
Interdisziplinäre Endoskopie
Universitätsklinikum Eppendorf
Martinistr. 52
20251 Hamburg
Germany

Dr. J. Schick
Generalbevollmächtigter
Sana Kliniken AG
Fanningerstr. 32
10365 Berlin
Germany

Prof. Dr. T. Schiedeck
Allgemeine Chirurgie
Klinikum Ludwigsburg
Posilipostr. 4
71640 Ludwigsburg
Germany

Dr. H. Schmidt
Internist
Bahnhofstr. 18
13125 Berlin
Germany

Prof. Dr. W. Schmitt
Innere Medizin I
Städtisches Klinikum München
Klinikum Neuperlach
Oskar-Maria-Graf-Ring 51
81737 München
Germany

Prof. Dr. F. Schreiber
Medizinische Universität Graz
Abteilung für Gastroenterologie
und Hepatologie
Auenbruggerplatz 15
8036 Graz
Austria

Prof. Dr. H.-J. Schulz
Innere Medizin
Sana-Klinikum Lichtenberg
Oskar-Ziethen-Krankenhaus
Fanningerstr. 32
10365 Berlin
Germany

Prof. Dr. P.D. Siersema
Academisch Ziekenhuis Utrecht
Afd. MDL
Heidelberglaan 100
3584 CX Utrecht
Netherlands

Dr. N. Städtler
Internist
Kiefholzstr. 250
12437 Berlin
Germany

Prof. Dr. C. Stroszczyński
Röntgendiagnostik
Universitätsklinikum Regensburg
93042 Regensburg
Germany

Dr. W. Veltzke-Schlieker
Hepatologie/Gastroenterologie
Charité – Universitätsmedizin
Campus Virchow-Klinikum (CVK)
Augustenburger Platz 1
13353 Berlin
Germany

Prof. Dr. B. Wiedenmann
Hepatologie/Gastroenterologie
Charité – Universitätsmedizin
Campus Virchow-Klinikum (CVK)
Augustenburger Platz 1
13353 Berlin
Germany

K. Wietfeld
Ltd. Endoskopiefachschwester
Klinikum Vest
Paracelsus-Klinik Marl
Lipper Weg 11
45770 Marl
Germany

Prof. Dr. M. Zeitz
Gastroenterologie
Charité – Universitätsmedizin
Campus Benjamin Franklin (CBF)
Hindenburgdamm 30
12203 Berlin
Germany

Rare forms of esophagitis: Esophageal candidosis and actinomycosis

S. Maev, I. Lupaşco, V.-T. Dumbrava
State University of Medicine and Pharmacy, Chisinau, Moldova

Introduction: Esophagitis caused by fungi and actinomyces rarely found in medical practice, affect especially immunocompromised patients. The diagnosis of esophageal and gastric actinomycosis is established very late and is often confused with malignant pathology.

Fungi esophagitis complications are: esophageal perforation that leads to mediastinitis, infection dissemination, esophageal stenosis and upper digestive haemorrhage.

Methods: Two cases of esophagitis in patients who suffer from hepatic cirrhosis caused by chronic viral C hepatitis.

Results: First case is a woman of 45 years old with the diagnosis of chronic viral hepatitis C (Child-Pugh stage B) and chronic alcoholism. During first examination she complained about: retrosternal pain during deglutition process, pain in the epigastric region, nausea and loss of appetite. At the ENT examination there was determined oropharyngeal candidosis. At the FEGDS: second grade diffused esophageal candidosis, second and third grade esophageal varices. At the mycologic examination: *Candida* spp. is sensitive to Nystatin, Amfotericin B, Itraconazole. The indicated treatment was: Itraconazole 100 mg per day for a period of 14 days, oral cavity embrocation with Nystatin 500,000 UI x 4 times per day, in association with gastroprotective medication. After 14 days of antimycotic treatment at the ENT, FEGDS and mycologic examination the wasn't determined any sign of candidosis.

Second case is a man of 57 years old who suffers from chronic viral hepatitis C (Child-Pugh stage A). At the first examination he complained of: moderate physical fatigue, epigastral pain. During FEGDS in the esophagus: an erythematous node, second and third grade magistral esophageal varices, and on the big curvature of the stomach: 3 polyps on a wide foot of 1.5 x 2 cm. At the pathohistologic analysis of gastric biopate there were described fragments of gastric mucosa with acute inflammation and fragments from leukocyte and fibrinous exudate with micelle elements characteristic to actinomycosis. There was initiated treatment with ceftriaxone 2.0/day i.v.; metronidazole 1.0/day i.v., for a period of 14 days, with a clinical and paraclinical positive dynamics.

Discussion/Conclusion: If to take in consideration that actinomycosis is a granulomatous pathology with bacterial etiology (*Actinomyces Israelii*) that tends to supurate and abcedate, the right establishment of the diagnosis and quick initiation of the appropriate treatment leads to healing and prevents possible complications. Adequate antimycotic treatment can be effective in candida esophagitis even in immunocompromised patients.

2

Duodeno-gastro-esophageal reflux (DGER) in symptomatic GERD patients with cholecystectomy

Simona Manea, Elena Gologan, Gheorghe Balan
University of Medicine and Pharmacy, Iasi, Romania

Introduction: Severe duodeno-gastro-esophageal reflux (DGER) is a risk factor for esophagitis and Barrett's esophagus. Clinical and epidemiological data suggest a potential association between cholecystectomy (CCE) and augmented bile reflux.

Methods: 170 patients (136 women, 31 males, median age 54.4 years) with typical symptoms of GERD and cholecystectomized were enrolled in the study (CCE-group: n = 170 patients) and non-cholecystectomized (nCCE-group: n = 68 patients, 34 women and 34 males, median age 51.7) patients. Standardized clinical work-up of patients included combined esophageal Bilitec 2000 esophageal manometry and upper endoscopy.

Results: In the statistical analysis no differences between the cholecystectomized group (CCE-group) and the patients without cholecystectomy (nCCE-group) could be observed in quantity or quality of reflux symptoms. Furthermore, bile reflux or severity of inflammation and frequency of Barrett's esophagus significantly differed between the nCCE and CCE-group. Moreover, the CCE-group revealed significant higher levels of pathological DGER compared to the nCCE-group ($20.29\% \pm 16.0$ vs. $8.67\% \pm 4.20317$; $p = 0.000$).

Discussion/Conclusion: To conclude, our data provide the evidence of elevated DGER after CCE in patients with typical clinical symptoms of GERD using the Bilitec device. Both the frequency and the extent of DGER was significantly increased in the CCE-group.

Biodegradable oesophageal stents for refractory benign disease: A case series

S. Hazeldine^{1,*}, J. Wu¹, R. Law², R. Przemioslo¹

¹Gastroenterology, ²Frenchay Hospital, Bristol, United Kingdom

Introduction: Benign oesophageal strictures that are refractory to dilatation are difficult to treat and may require the placement of an oesophageal stent. Biodegradable oesophageal stents (BDOS) are licensed for use in benign oesophageal strictures including achalasia. We report our experience of BDOS in patients with refractory benign oesophageal strictures.

Methods: Patients were considered to have refractory benign oesophageal strictures if histology was negative for malignancy and had undergone at least 3 previous balloon dilatation procedures. Ella BD[®] Polydioxanone stents (UK Medical) were placed under endoscopic and fluoroscopic visualisation. Stent position and function was checked the following day with a barium swallow. Patients were then followed up clinically, recording dysphagia symptoms, stent migration and complications.

Results: Four patients were identified with refractory benign oesophageal strictures. Mean age 68 (57–87), 3 male and 1 female. Stricture aetiology; 2 achalasia, 1 peptic and 1 post-radiotherapy. Follow-up period post-stent insertion ranged from 1 to 7 months. On initial inspection all 4 stents were placed correctly. Follow-up barium swallow on day 1 showed one stent had migrated distally (achalasia), this was replaced in the correct position endoscopically. At day 7, dysphagia was not relieved in 1 of 4 patients (achalasia), despite adequate stent patency. At 1 month only 1 of 4 patients had symptom relief (peptic stricture) and was still symptom free at 7 months. Complications included severe odynophagia requiring stent removal (post-radiation), food bolus obstruction and aspiration pneumonia (achalasia).

Discussion/Conclusion: We have experienced variable success in our use of biodegradable stents. In our experience BDOS did not provide significant benefit in those patients with achalasia especially if it was longstanding and there was poor oesophageal motility. Only one patient (peptic stricture) had a prolonged response to dysphagia. Larger case series are required to ascertain the role of BDOS in these patients.

4

Genotyping of *Helicobacter pylori* strains from endoscopic biopsy

Semire Uzun¹, Ahmet Aslan², Muhyittin Temiz², Sibel Hakverdi³, Birgül Özcan⁴, Çağrı Güleç⁵, Elif Özkök⁶

¹Biophysics Department, ²General Surgery Department, ³Pathology Department of Medical Faculty and ⁴Biology Department of Natural Science Faculty of Mustafa Kemal University, Antakya-Hatay, Turkey

⁵Genetics Department ⁶Molecular Neuroscience Department of Institute for Experimental Medicine Research, Istanbul University, İstanbul, Turkey

Objective: *Helicobacter pylori* (Hp) infection may show wide range of clinical signs from subclinic mild-gastritis to ulcerations or neoplastic processes, depending on virulence factors of infecting bacterial strains. Genotyping studies show that, the bacterial strains with cytotoxin-associated (CagA) gene and some subtypes of Vacuolating-cytotoxin (VacA) gene, encoding proteins with cytotoxic activity on host tissue are associated with more severe clinical outcome.

Materials/Methods: Genotyped the VacA gene subtypes and tested the presence of CagA pathogenicity islands by multiplex PCR method, in biopsy specimen obtained endoscopically from stomach of dyspeptic patients from Hatay region of Turkey

Results: Gastric biopsy specimens of 66 dyspeptic patients are obtained endoscopically. The mean age was 49 ± 15 (30 male, 36 female). Hp infection was found in 57.6% of cases and 73.7% of positive cases were infected with virulent strains. 68.4% were CagA positive and 39.5% were carrying all the three high risk allele together. Furthermore mixed infection was found in 10 cases (26.3%).

Conclusions: Different aspects are present on curing patients with Hp using combined antibiotics due to troubles, expenses of therapy and development of antibiotic resistance while this infection is totally curable. Our suggestion is that the patients with virulent strains should absolutely be cured because of probability to develop atrophic gastritis and gastric neoplasia and risks of transmission of these virulent strains to healthy people and epidemic.

The efficacy of triple therapy treatment with probiotics in eradicating *Helicobacter pylori* infection in gastroduodenal ulcers

I. Copaci, L. Micu, A.V. Ditoiu, M. Voiculescu

Center of Internal Medicine, Fundeni Clinical Institute, Bucharest, Romania

Introduction: The efficacy of standard triple therapy for eradication of *Helicobacter pylori* (Hp) infection has a 25% failure rate. Therefore, the application of new approaches to improve the efficacy of triple therapy is clinically important.

Methods: We tested the efficacy of simultaneous treatment with Lactobacillus-containing probiotic and triple therapy in eradicating Hp in patients with chronic gastroduodenal ulcers. 88 pts (M:F 50:38, mean age 43.8 ± 10.6 years) with Hp positive chronic gastroduodenal ulcers were randomly assigned in equal numbers to either a Lactobacillus-containing probiotic plus triple therapy group or a triple therapy-only group. The patients received 10 days of triple therapy (amoxicillin and clarithromycin plus pantoprazol with or without simultaneous treatment with Protectis[®] (one tablet contains 100 million Lactobacillus reuteri Protectis[®]), 1 tablet/day. Pre- and post-treatment upper GI endoscopy with 6 gastric biopsies (antrum 3, body 3) were taken to assess the status of Hp infection and ulcer disease. Histology (Giemsa stain) and rapid urease test were performed to detect H. pylori infection.

Results: Baseline characteristics of probiotic versus standard triple therapy were: mean age 43.45 ± 14 years vs. 46.8 ± 17 years, male/female ratio 24/20 vs. 26/18 and smoker/non-smoker status 20/24 vs. 18/26 respectively. The probiotic plus triple therapy group had a higher Hp eradication rate than presented the triple therapy-only group (88.6% compared to 72.7%; $p < 0.05$) and intention to treat (ITT) analysis 80% vs. 77% respectively. Moreover, the adverse effects of triple therapy were evidently lower in the probiotic plus triple therapy group (9%) than in the triple therapy-only group (25%; $p < 0.02$).

Discussion/Conclusion: The simultaneous treatment with Lactobacillus-containing probiotic can decrease *Helicobacter pylori* loads and frequency of side effects, thus improving the efficacy of triple therapy in eradicating H. pylori.

The occurrence of pathological changes in the gastric mucosa in patients taking antiplatelet agents

M. Korzonek*, A. Biskupski**, M. Brykczyński**

*Department of Digestive Endoscopy

**Clinical Department of Cardiosurgery

Pomeranian Medical University of Szczecin, Poland

Introductions: In recent years new antiplatelet agents have been introduced in cardiological treatment. These agents found application in patients suffering from stable coronary artery disease and acute coronary syndromes, mostly in patients with stent implanted into a coronary artery. Impact of applied antiplatelet treatment on the gastric mucosa was studied on these patients, qualified for cardiosurgical treatment and bypass operation.

Methods: 70 patients, 17 women and 53 men (average age of women 65.8, average age of men 60.0) awaiting cardiosurgical bypass operation were examined. 17 patients (24% of patients examined) suffered from acute coronary syndrome, 22 (31.4%) patients suffered from stable coronary artery disease, 31 (44.2%) patients underwent myocardial infarction, 19 (27.1%) patients had a stent implanted into a coronary artery and 21 (30%) were diabetics. All patients took clopidogrel in a dose 75 mg per 24 hours and salicylic acid in a dose 75 mg per 24 hours. No patient used proton pump inhibitors.

All patients were qualified for a bypass operations in extracorporeal circulation. Before operation these patients underwent endoscopic examination to assess changes in the gastric mucosa.

Results: In 2 patients (2.8% of patients examined) gastric ulcer was found, in 2 (2.8%) patients duodenal ulcer, in 5 (7.1%) erosive gastritis, in 9 (12.8%) erosions in the stomach and duodenum, in 22 (31%) stomach inflammatory changes, in 2 (2.8%) inflammation of duodenum. No pathological changes were found in 28 (40%) patients. Patients with pathological changes in the gastric mucosa underwent PPI treatment followed by endoscopic examination. Only after a complete healing of changes were patients recommended to a cardiosurgical operation. Owing to that, there were no complications in the form of bleeding from digestive tract after surgery.

Conclusions: Antiplatelet treatment in patients ordered to heart cardiosurgical operations in extracorporeal circulation should previously undergo gastroscopic examination to find pathological changes in the gastric mucosa.

Healing pathological changes in the stomach and duodenum prevents complications in the form of bleeding from digestive tract after heart operation.

Laparoscopic treatment for focal liver malformations

J. Pósan, Z. Szentkereszty, I. Takács, R. Kotán, L. Sasi Szabó, P. Sápy, L. Damjanovich
Institute of Surgery, University of Debrecen Medical and Health Science Center, Debrecen, Hungary

Introduction: Recently the laparoscopic approach to liver operation has been more frequently and this technique is becoming widespread mainly for benign neoplasms. To analyze retrospectively the outcome of laparoscopic liver interventions performed between 2005 and 2010.

Methods: 35 liver resections and 20 liver cyst fenestrations (without polycystic liver) were performed in this period in our department via laparoscopy. Male to female ratio was 13:42.

Results: Indications for the resections were the followings: focal nodular hyperplasia (n = 9), haemangioma (n = 7), simple cyst (n = 4), echinococcus cyst (n = 3), adenoma (n = 1), biliary dysplasia (n = 2), other benign tumor (n = 9); deroofting procedure was performed because of simple cyst of the liver in 20 cases. The average tumor size was 35 (10–90) mm and the average diameter of the cysts were 75 (30–120) mm. Regarding resection types anatomical segment resections, pericystectomies and non-anatomical resections were performed in 7, 3 and 25 cases. Conversion was only required during some liver resections (n = 3) The postoperative morbidity was 17% regarding the resections and 10% in cases of fenestrations. Overall mortality was 0%. One reoperation was performed because of bile leakage.

Discussion/Conclusion: Laparoscopic liver resection and fenestration can be recommended when allowed by the anatomical situation. Applying the proper surgical technique, laparoscopic liver interventions can be performed safely and the postoperative complication can be minimized.

Hepatobiliary complications in IBD

Paul Mitrut, Anca Oana Mitrut, Andreea Marinas, Amelia Genunche-Dumitrescu, Daniela Badea, Aurelia Enescu
University of Medicine and Pharmacy, Craiova, Dolj, Romania

Introduction: In rare cases the liver and gallbladder are found to be involved in the bowel inflammation in Crohn's disease and ulcerative colitis. Nodular cell proliferation, known as "granulomas", also develop in the liver tissue and the antibodies present in Crohn's disease may also react with the surface of the bile ducts.

Aim of study: To investigate the incidence and the profile complications' liver and gallbladder in Crohn's disease and ulcerative colitis.

Patients and methods: The study was performed in Second Medical Department of Emergency District Hospital of Craiova on a group of 71 patients known with Crohn's disease and 156 patients with ulcerative colitis. Statistically analysis pointed out the prevalence of male 74.5%; median ages 46.9 years; range 21–69 years. The diagnostic of Crohn's disease and ulcerative colitis was made in all cases by colonoscopy and biopsy examination. The research protocol contained a clinical, biological, histological and a complete imagistic evaluation of the liver and port system (MRI technology).

Results and discussions: The liver determination was present at 14.09% (32 patients) of cases with the following ethyological spectrum: primary sclerosing cholangitis 7 cases, pericholangitis 6 cases, primary biliary cirrhosis 5 cases, steatofibrosis 7 cases, cholangiocarcinoma 2 cases and liver cirrhosis 5 cases. In these cases the diagnostic was confirmed by biopsy and histological examination and RMN cholangiography.

Primary sclerosing cholangitis is often associated with inflammatory bowel disease of the colon – although one or the other may predate the diagnosis of the other by several decades.

Conclusion: The liver determination in IBD is frequently. Specifically was primary sclerosing cholangitis, pericholangitis, steatofibrosis and liver cirrhosis. At patients with IBD is necessary complete evaluation (biological and histological) of the liver.

Factors that influence the initial successful endoscopic management for biliary stricture after living donor liver transplantation (LDLT)

Jin Yong Kim, Sung June Eo, Kwang-Hyuck Lee

Department of Medicine, Samsung Medical Center, Sungkyunkwan University School of Medicine, Seoul, Republic of Korea

Introduction: Biliary strictures are one of the major causes of morbidity and mortality in liver transplantation (LT) recipients. Endoscopic management for biliary stricture following living donor liver transplantation (LDLT) is not well established as a treatment option compared to deceased donor liver transplantation (DDLT).

Methods: 137 adult patients who underwent LDLT and were confirmed to have biliary stricture by endoscopic retrograde cholangiopancreatography (ERCP) were evaluated. Biliary strictures were primarily managed endoscopically with internal drainage or nasobiliary catheterization.

Results: The initial success rate of initial endoscopic management for biliary stricture following LDLT was 46.9% (67 of 137 patients), and was dependent on the interval between the detection of biliary stricture and the time of ERCP. Also, cholangiographic findings such as the shape of stricture site and the shape of distal duct tip are important factors for successful endoscopic treatment..

Discussion/Conclusion: When biliary strictures are suspected after LDLT, prompt endoscopic intervention is needed to increase the success rate of endoscopic management.

In addition, successful endoscopic management is predictable by cholangiographic findings, which may guide a choice of therapeutic modality.

Therapeutic ERCP application analysis in elderly patients with choledocholithiasis

Baiba Putnina¹, Aldis Pukitis²

¹Riga Stradins University, Riga, Latvia

²University of Latvia, Riga, Latvia

Introduction: The most prevalent coexisting conditions for elderly patients undergoing endoscopic retrograde cholangiopancreatography (ERCP) are: long-term disease, medication use, anatomical changes, which limit the procedure time, application of ERCP techniques. Our aim was to analyze ERCP application/efficiency for patients aged over 60 years with choledocholithiasis.

Methods: 361 patient (200 female and 161 male) aged above 60 with choledocholithiasis, who undergone therapeutic ERCP in Paula Stradina Clinical University Hospital were included. For statistical processing categorized values (Pearson's χ^2 test), quantitative characteristics and parametric single factor analysis of variance (ANOVA, SPSS for Windows 17.0) was used.

Results: Papillotomy with papillotom was done in 283 cases (p 0.204, OR 1.665, 95% CI: 0.648–4.276, RR 1.249, 95% CI: 0.783–1.994), basket extraction in 43 cases (p 0.554, OR 0.858, 95% CI: 0.516–1.426, RR 0.942, 95% CI: 0.766–1.157), balloon extraction in 38 cases (p 0.435, OR 0.922, 95% CI: 0.535–1.586, RR 0.969, 95% CI: 0.782–1.200). Combined basket and balloon extraction in 32 cases (p 0.442, OR 1.101, 95% CI: 0.598–2.026, RR 1.036, 95% CI: 0.831–1.293). Mechanical lithotripsy with basket and balloon extraction in 14 cases (p 0.419, OR 1.237, 95% CI: 0.490–3.127, RR 1.079, 95% CI: 0.791–1.473), mechanical lithotripsy in 59 cases (p < 0.001, OR 2.769, 95% CI: 1.518–5.049, RR 1.358, 95% CI: 1.179–1.565).

Discussion/Conclusion: The main age group was 60–79 years. Our data showed the trend to increase of high risk ERCP procedures for the elderly patients (mechanical lithotripsy was performed in 79.7% cases).

Endoscopic treatment of biliary obstruction due to alien bodies and parasites

V. Kolomyitsev, O. Kushniruk, M. Pavlovsky
Lviv Medical University, Lviv, Ukraine

Introduction: We present our experience of endoscopic diagnosis and treatment in case of biliary obstruction due to alien bodies and parasites.

Methods: During the last 10 years, 5283 patients were underwent to endoscopic retrograde cholangiography (ERC) for diagnosis and treatment with sphincterotomy. 5 patients had obstruction with broken external biliary drainage; 14 patients - with dislocated stent; 6 patients-with parasites (5 patient with Fasciola Hepatica and a patient with Ascaris lumbricoides); one patient – with ligature obstruction, and another one – with 45 cm suture material. For correct diagnosis, ultrasonography, X-ray, CT, MRCP and ERC were used.

Results: After sphincterotomy, alien bodies and parasites were successfully removed. Methods of alien bodie fixation and extraction depended on size and shape of object. After endoscopic removing of alien bodies and parasites patients had fast relief from the complications with the help of medications.

Discussion/Conclusion: Endoscopic retrograde cholangiography and sphincterotomy in the patients with biliary obstruction by alien bodies and parasites should prevent late complications, delay in treatment, and avoid laparotomy.

A duodenal duplication cyst as a cause of pancreatitis in an adolescent girl

Martin Laaß¹, Kathrin Wieczorek², Gabriele Hahn³, Guido Fitze⁴

¹University Children's Hospital, Technical University, Dresden, Germany

²Department of Pathology, Technical University Dresden, Germany

³Department of Radiology, Technical University Dresden, Germany

⁴Department of Pediatric Surgery, Technical University, Dresden, Germany

Introduction: Duodenal duplication cysts are rare congenital malformations which can cause acute pancreatitis or biliary obstruction. Symptomatic cases should be treated by surgical resection, which can be complex due to the close proximity of the cyst to the major duodenal papilla.

Case report: A 15-year-old otherwise healthy girl presented with a history of recurrent abdominal pain for eighteen months. Her lipase (33.2 $\mu\text{mol/s}^{\text{l}}$, normal < 1) and her pancreatic amylase (15.6 $\mu\text{mol/s}^{\text{l}}$, normal 0.22–0.88) values were markedly elevated. Transaminases were slightly increased: ALAT 1.05 $\mu\text{mol/l}^{\text{s}}$ (normal < 0.75), GGT 1.20 $\mu\text{mol/l}^{\text{s}}$ (normal < 0.48), but values for bilirubin and alkaline phosphatase were within normal limits.

Gastroduodenoscopy revealed a mass which almost completely filled the lumen of the descending duodenum, such that no papilla could be visualized. Endoscopic ultrasound showed a fluid-filled mass but was unable to discriminate between a duodenal and a choledochus cyst. An open laparotomy was performed and after incising the duodenum the cystic structure was examined and carefully excised. The opening of the pancreatic duct was found to be located on the outside wall of the cyst, and the opening of the bile duct on the inner side of the bile filled cyst. The cyst was resected save for the portion attached to the pancreatic and bile duct structures, which were left untouched. Histology demonstrated features typical of a duplication cyst: two duodenal mucosal layers (with muscularis mucosae but without muscularis propria), connected by a layer of submucosa.

Post surgery the patient remained well, with all laboratory test values falling within the normal range over a follow-up period of 16 months.

Conclusion: Congenital duodenal duplication cysts may become symptomatic even in adolescence and must be included within the differential diagnosis of recurrent pancreatitis or abdominal pain within this age group. When symptomatic, they should be treated surgically by resection or endoscopically by cyst marsupialization into the duodenum. If surgical or endoscopic intervention can be performed without damaging the pancreatic or biliary ducts, the long-term outcome for patients is excellent.

Analysis of clinical course in severe acute biliary and non-biliary pancreatitis: A comparative study

R. Kotán, J. Pósn, Z. Szentkereszty, L. Sasi Szabó, P. Sápy, L. Damjanovich
Institute of Surgery, University of Debrecen Medical and Health Science Center,
Debrecen, Hungary

Introduction: The acute pancreatitis is a relative common disease with incidence of between 5 and 80 people per 100,000 of the population. The number of new cases in the last years has steadily increased. The two main etiological factors are alcohol and cholelithiasis. The incidence of alcoholic pancreatitis is higher in male, and the incidence of gallstone pancreatitis higher in female.

The aim of this study is to summarise the difference between the clinical course of biliary and non-biliary type of severe acute pancreatitis by analysing the data of these patients.

Methods: The 139 patients treated with severe acute pancreatitis were divided in two groups: biliary (A group) and non-biliary (B group) in origin. The two groups were compared on the basis of sex and age, mortality, morbidity, number of surgery and hospital stay. χ^2 probe was used for the statistical analysis.

Results: The complications in the biliary group were more serious. The mortality was 15.1% in all cases and was 17.8% in the group A and 13.8% in the group B. The mortality rate of the female were significantly higher in the group A.

Discussion/Conclusion: There are higher morbidity and mortality rate by the female patients suffered from severe biliary acute pancreatitis. Therefore in old female patients with serious comorbidity and gallstones, before developing the complications an elective cholecystectomy is suggested.

Pancreatic pseudocysts: Long-term results of endoscopic and surgical treatment

O. Kushniruk, V. Kolomiytsev
Lviv Medical University, Lviv, Ukraine

Introduction: To learn the efficacy of endoscopic (ED) and conventional surgical drainages (SD) in the management of pancreatic pseudocysts (PP), and to compare long-term recurrence rate and quality of life (QL).

Methods: 126 patients with symptomatic PP (size 3–19 cm) were treated during last 10 years. PP were connected with main pancreatic duct in 112 (89%) patients. ED was performed in 82 and SD in 44 cases. Endoscopic transmural (ETD) approach was used in case of luminal compression of PP without portal hypertension; other patients of ED-group underwent to endoscopic ultrasound-guided drainage (EUD). Short-term complication rates, long-term results, and QL by the written questionnaire SF-36 in 12–36 months after procedure were compared.

Results: 55 patients underwent to ETD, and 27 – to EUD. Minor complications occurred in 13 (15.8%) patients: bleeding, cyst leakage, stent dislocation, secondary infection, and pneumoperitoneum. Complications, except one, were managed conservatively or by endoscopic procedures. There was no bleeding in EUD group. After SD 15 (34.0%) patients had complications with mortality 4.5% (2 cases). 60 (73.1%) and 33 (75.0%) patients of ED and SD groups respectively were followed-up. Long-term PP recurrence was observed in 5 (8.3%) after ED and in 9 (27.2%) after SD. 4 recurrent cases after SD were treated by ED. Patients after endoscopic approaches had statistically better values of Physical and Mental Health, Physical and Role-Physical Functioning, Vitality and Body Pain in comparison with surgery group ($p < 0.05$).

Conclusion: Endoscopic drainage is effective and safe treatment of patients with PP. Patients after ED are better adapted to the main disease in long-term follow-up period with less psycho-somatic disorders, higher diligence and QL in comparison with patients after surgery.

Celiac disease – A retrospective study

Elena Gologan¹, Gabriela Stefanescu¹, Simona Manea¹, Dorin Achitei², Roxana Bocan², Catalina Motea², Cristian Ciobanu², ¹Gheorghe Balan¹

¹University of Medicine and Pharmacy, Iasi, Romania

²Institute of Gastroenterology and Hepatology, Iasi, Romania

Introduction: Celiac disease is a rare cause of anemia in adults with no digestive diseases in their medical history.

Methods: A cohort of 55 adults with chronic hyposideremic anemia, no diarrhea and normal findings at upper digestive endoscopy, colonoscopy and small bowel X-ray examination were investigated in the Institute of Gastroenterology and Hepatology, Iasi, Romania between January 2006 and June 2010 by: duodenal biopsies and Celikey test (anti-tissue transglutaminase antibodies IgA) to confirm celiac disease.

Results: 55 adults (age between 18 and 44 years, mean age 23.5) admitted in the Institute of Gastroenterology and Hepatology, Iasi, Romania between January 2006 and June 2010 were investigated in order to identify celiac disease by duodenal biopsies and Celikey test. 29 of them (16 female and 13 male), had both test conclusive, 11 of the rest had Marsh I duodenal atrophy but negative Celikey test and only one positive Celikey test with normal duodenal histology. The therapeutic test was positive in 28 of 29 cases (96.5%) from the first group (the non-responding one was set on corticotherapy with a good response), in only 3 cases from the second group (27.3%) and the single patient of the third group; totally in 32 cases (78%).

Discussion/Conclusion: A hyposideremic anemia in young adults even with no diarrhea and normal endoscopic findings may hide a celiac disease, the confirmation requiring usual laboratory and endoscopic investigations and the therapeutic test is very easy to perform.

3D-MAGMA: A novel way of measuring motility in infectious diarrhea (ID)

J. Felber¹, S. Paetzold², H. Richert³, A. Stallmach¹

¹University Hospital Jena Jena, Thuringia, Germany

²Klinikum Altenburger Land, Altenburg, Thuringia, Germany

³Innovent Technologieentwicklung, Jena, Thuringia, Germany

Introduction: The current means of measuring gut motility are limited. Diarrheal symptoms a frequent problem in clinical practise can be explained by abnormalities in absorption and secretion of fluids but also by motility changes.

Methods: 20 healthy volunteers and 7 patients with ID underwent motility testing of the small bowel by a magnetic detection system (3D-MAGMA). A technique allowing the tracking of a magnetic capsule in a three-dimensional space by sensors placed above a supine patient.

Results: The pacemaker frequency in patients with ID (median: 10.6; min-max: 8.4–11.8; [cpm]) did not differ from that in healthy controls (median: 10.7; min-max: 8.4–12.9). The capsule in patients with diarrheal symptoms covered a greater distance in the first hour after leaving the stomach (controls: median: 150; min-max: 82–262; ID: median: 175; min-max: 135–315; [cm]).

The time proportion of spike-wave activity (> 0.2 cm/s) in the duodenum was higher in all participants compared to the jejunum as was the velocity of the capsule in the duodenum. While patients with ID showed an increase of strong spike-wave activity (> 0.5 cm/s) in the jejunum compared to the duodenum, strong spike-wave activity was absent in the jejunum of controls.

For both groups a negative correlation could be found for the time proportion of spike-wave activity and the length of time the capsule spent in the duodenum (controls: $r_s = -0.95$; $p < 0.0001$; ID: $r_s = -0.91$; $p = 0.004$). While this could also be shown in the jejunum for controls the correlation was lost in ID (controls: $r_s = -0.91$; $p < 0.0001$; ID: $r_s = -0.62$; $p = 0.14$).

Discussion/Conclusion: Abnormalities in small bowel motility especially in the distal small bowel are of importance in developing symptoms. Magnetic marker monitoring enhances the understanding of the underlying pathophysiology.

Duodenal lymphangiectasia scoring system based on magnifying endoscopy with NBI

S. Belyavskaja, K. Marahovsky

Republican Scientifically Practical Center “Mother and Child”, Minsk, Belarus

Introduction: The prevalence and clinical significance of the incidentally found lymphangiectasia in the duodenum during upper gastrointestinal endoscopy are not yet known. The aim of this study was to evaluate magnifying endoscopic features of duodenal lymphangiectasia incidentally found during upper gastrointestinal endoscopy.

Methods: From November 2009 to November 2010, 155 enhanced magnification upper gastrointestinal endoscopy were performed on 95 children and 60 adult patients. Among 155 patients duodenal lymphangiectasia was suspected in 46 cases (30%): 29 children aged 6–17 and 17 adults aged 22–59. Endoscopic features of duodenal lymphangiectasia were classified into three types: (1) multiple scattered pinpoint white spots; (2) diffuse prominent villi with whitish-discolored tips; and (3) focal small whitish macule or nodule, according J.H. Kim et al. 2009.

But this and majority of other known classification of duodenal lymphangiectasia are based on conventional endoscopy. Magnification endoscopy visualize structural unit of duodenal mucosa – single villus and more over epithelium of intestinal villus and intravillous capillaries in case of NBI using.

Results: Magnifying endoscopy scoring system of duodenal lymphangiectasia was classified according to the severity of lymphatic duct dilatations and viewing capillaries.

Base classification was scored – first type – 6 point, second – 3 point and third one point. After live endoscopy two experts evaluated digital video fail. Scoring system for one villus was performed.

spread of lymphangiectasia: half of villi (1) or whole villi (2)

grade of white color: low whitening (1) or high grade whitening (2)

deformation of villi: yes (1) or no (0)

intravillous capillaries: visible (0) or invisible (1)

Discussion/Conclusion: The scoring system based on magnifying endoscopy with NBI may be proposed to detail evaluation intestinal lymphangiectasia and to precise their localization in villi.

Excavated lesions in small bowel found during capsule endoscopy correlates with patient vital signs

A. Derovs¹, J. Derova², J. Pokrotnieks¹

¹Riga Stradin University, Riga, Latvia

²Latvian Maritime Medical Centre, Riga, Latvia

Introduction: One of the basic mucosal lesion types in small bowel (SB) can be classified as excavated (EL). Authors propose hypothesis that there is a correlation between EL in SB and patient vital signs (PVS).

Aim of study: To evaluate possible correlation between EL in SB found during capsule endoscopy (CE) and PVS (height, weight, waist perimeter [WP], Body Mass Index [BMI]).

Methods: From authors' CE database has been chosen patients with EL in SB found during CE. EL were defined regarding to *Minimal Standard Terminology Digestive Endoscopy – MST3.0*. BMI was calculated using the standard formula.

Results: In total from 217 patients, 137 cases, which satisfied inclusion criteria, were analyzed. Patients weight was from 28 to 114 kg (70.14 ± 17.44), height – 150 to 198 cm (169.90 ± 8.40), WP – 52 to 120 cm (87.29 ± 14.28), BMI – 12.44 to 39.45 (24.18 ± 5.34). Positive correlation (PC) was observed between EL in SB and patients weight ($p = 0.009$). Negative correlation was observed between ulcers in SB and patients height ($p = 0.031$). Weak PC was observed between aphtae/erosions and BMI ($p = 0.066$). PC was found between EL and WP ($p = 0.027$).

Discussion/Conclusion: EL in SB correlates with patients' weight and WP. There is a negative correlation between ulcers in SB and height. There is weak correlation between aphtae/erosions and BMI.

Acknowledgement: This study was made with European Social Fund support.

Capsule endoscopy in protein losing enteropathy – Case report

G. Oracz, J. Kierkus, M. Dadalski, J. Ryzko
The Children's Memorial Health Institute, Warsaw, Poland

Introduction: Capsule endoscopy is promising method in the diagnosis of small bowel diseases. We report a girl with protein losing enteropathy (PLE).

Methods: At age of 13 she suddenly developed peripheral edema and ascites. Laboratory studies revealed decreased total protein concentration 2.9 g/dl, albumin concentration 1.6 g/dl; her fecal alpha1-antitrypsin concentration was increased – 21.4 mg/g stool (reference value 0.66–1.81 mg/g stool). Despite frequent infusions of protein her albumin level was low.

Results: Esophagogastroduodenoscopy demonstrates normal picture of esophagus and stomach. White “dots” supposed to be lymphangiectases were found in duodenum. Colonoscopy was normal. Duodenal biopsy showed normal intestinal mucosa with dilated lymph vessels. To determine range of changes and suitable treatment (surgery or preservative treatment) capsule endoscopy (M2A) was performed. Small bowel transit time was 2 hours 33 minutes. Capsule endoscopy demonstrated lymphangiectasies in the duodenum only. The remaining small bowel was normal. High protein diet with MCT oil was used in her nutritional therapy. 6 months follow-up surveillance showed dramatic improvement in symptoms and increase in serum total protein concentration (5.8 g/dl).

Discussion/Conclusion:

1. Capsule endoscopy is helpful in the diagnosis of cause protein losing enteropathy.
2. Capsule endoscopy should be considered complementary but not alternative to endoscopy.

Therapeutic DBE: A bi-national, three-center experience

Ivan Jovanovic^{1,2}, Klaus Vormbrock², Lucia C. Fry^{2,3}, Srdjan Djuranovic¹, Milenko Ugljesic¹, Marzena Zabielski², Peter Malfertheiner³, Klaus Mönkemüller^{2,3}

^{1,2}Clinic for Gastroenterology and Hepatology, Clinical Center of Serbia, Faculty of Medicine, University of Belgrade, Serbia

²Department of Internal Medicine and Gastroenterology, Marienhospital, Bottrop, Germany

³Department of Gastroenterology, Hepatology and Infectious Diseases, Otto-von-Guericke University, Magdeburg, Germany

Introduction: There are few reports focusing on therapeutic small bowel endoscopy. The aim of our study was to analyze the results of therapeutic small bowel endoscopy in a large cohort of patients.

Methods: Retrospective study of prospectively collected database comprising all patients undergoing diagnostic and therapeutic small bowel endoscopy in three centers. The following data were collected: patients' demographic data, indications for examination, results of previous non-invasive small bowel imaging test, duration of the procedure, amount of sedative agent and results of the procedure including findings, endoscopic interventions, complications and pathological report.

Results: A total of 614 double balloon enteroscopies (DBE) were performed in 534 patients. The most common pathological findings were angiodysplasias and vascular lesions (n = 98, 18%), mucosal ulcers and erosions (i.e. inflammation, ischemia) (n = 95, 17.8%), polyps and tumors (including patients with familial polyposis syndrome such as Peutz-Jeghers syndrome (PJS), familial adenomatous polyposis syndrome (FAP), neurofibromatosis, adenocarcinoma, neuroendocrine tumors and gastrointestinal stromal tumors (n = 52, 9.7%), strictures (Crohn's disease, ischemia, tumors) (n = 12, 2.2%). The mean duration of therapeutic small bowel endoscopy was 67 minutes (range 30–115) compared to 50 minutes in diagnostic procedures (range 25–105) (p < 0.05).

A therapeutic small bowel endoscopy was performed in 121 patients (22%). Therapeutic procedures included argon-plasma-coagulation (APC) of vascular lesions (n = 73), polypectomy (n = 49), mucosectomy (n = 5), stricture dilation (n = 7), foreign body extraction (n = 7), injection of fibrin glue (n = 10), clip placement (n = 5). There were a total of 5 complications (0.9%; paralytic ileus, n = 2, pancreatitis, n = 1, bleeding n = 2). No perforation or death occurred.

Discussion/Conclusion: Endoscopists performing DBE should be trained and prepared to provide therapeutic interventions for small bowel disorders including APC, injection, hemoclipping, polypectomy, mucosectomy and foreign body extraction. Therapeutic small bowel endoscopy, albeit associated with complications in about 1% of cases, can be considered a relatively safe procedure.

Ileum examination is not the rule during colonoscopy exam

Andrei Haidar, Yosr Kardous, Badre Aznag, Alvin Ouchieng, Alina Zlate, Florin Musat, Claudia Vasiliu, Oana Panazan
Colentina Clinic Hospital, BIO-TERRAMED Medical Center, Bucharest, Romania

Ileum examination importance during colonoscopy at patients with no clear indication for the examination of the small intestine.

Introduction: Prospective Study realised in tertiary referral Hospital and outpatient endoscopy unit.

Methods: Between January 2008 and January 2011, in three medical centers, a number of 1640 patients aged 20–83 have had the terminal ileum examined. 1150 patients (70.12%) had been previously diagnosed and treated for irritable bowel syndrome.

Results: 236 (14.39%) patients have been found with lesions of the terminal ileum:

- 2 endocrine tumors (carcinoid) (0.84%)
- 8 adenoma polyps (3.389%)
- 5 cases of angioplastic lesions (2.11%)
- 2 Merckel diverticules (0.84%)
- 1 adenocarcinoma (0.42%)
- 6 cases of enteritis with eosinophils (2.54%)
- 128 cases of Crohn disease (54.23%)
- 84 non-specific ileitis (35.59%)

Discussion/Conclusion:

1. Examination of the ileum during colonoscopy is achievable, with no extra funds and no complications, insuring a very successful diagnosis.
2. Diseases like Crohn, non-specific ileitis, eosinophilic enteritis, etc. are usually under-diagnosed, therefore the examination of the ileum can play a decisive role in the diagnosis of such diseases.
3. The diagnosis of irritable bowel syndrome is an exclusion one, thus the examination of the ileum during colonoscopy, should be a compulsory way of excluding and differentiating among different illnesses with similar symptoms.

Ileal biopsy in chronic diarrhea with normal appearing ileoscopy

Abdurrahim Sayilir¹, Mevlüt Kurt¹, Murat Kekilli¹, Ibrahim K. Onal¹, Yavuz Beyazit¹, Nesrin Turhan², Mehmet Ibiş¹, Mehmet Arhan¹

¹Department of Gastroenterology, ²Department of Pathology, Turkiye Yuksek Ihtisas Teaching and Research Hospital, Ankara, Turkey

Introduction: The aim of this study was to investigate diagnostic value of ileal biopsy in chronic non-bloody diarrhea despite normal appearance on endoscopy.

Methods: Patients who had terminal biopsies obtained during a colonoscopic procedure with endoscopically normal appearance between January 2008 and January 2010 were reviewed. Indications for colonoscopy were assessed in two groups; non-bloody diarrhea and non-diarrhea. Comparison of histopathological findings was made between the two groups.

Results: Screening of records of colonoscopies revealed 473 patients who underwent terminal ileum biopsy, 178 of which were excluded for various reasons. In total, the records of 295 patients were deemed suitable for the final analysis. The diarrhea group consisted of 135 patients who were investigated for chronic non-bloody diarrhea, while the remaining 160 patients formed the non-diarrhea group. Histopathological examination of terminal ileum biopsy specimens of patients in the diarrhea group revealed abnormal histology in 8 patients (5.9%) compared to 5 patients (3.1%) in the non-diarrhea group, with no statistically significant difference between the two ($P = 0.26$).

Discussion/Conclusion: Although obtaining a biopsy of the ileum despite a macroscopically normal appearance may seem to offer some added benefit in chronic non-bloody diarrhea, prospective trials are needed in order to assess the diagnostic value of terminal ileum biopsies in patients with diarrhea

An audit on the use of the SeHCAT test in chronic diarrhoeal illnesses

Neena Patel¹, Laura Davidson¹, Salil Singh², Kadukkavil Padmakumar²

¹School of Medicine, Manchester University, Manchester, United Kingdom

²Royal Bolton NHS Foundation Trust, Bolton, Lancashire, United Kingdom

Introduction: Bile acid malabsorption (BAM) occurs more frequently than generally believed and can be an important cause of chronic diarrhoea. Bile salt malabsorption (BAM) may be the underlying cause of chronic diarrhoea in up to 1/3rd of patients previously diagnosed with diarrhoea predominant IBS (D-IBS)

SeHCAT (23-seleno-25-homo-tauro-cholate scan) retention study determines the amount of bile acid that is being reabsorbed by the terminal ileum. It is considered to be an accurate method for diagnosing BAM. Retention of radio labelled selenium of less than 15% at day 7 was considered as an abnormal test. BAM has been classified as

- Type 1 – ileal dysfunction (secondary BAM)
- Type 2 – idiopathic bile acid malabsorption (IBAM)
- Type 3 – other conditions (cholecystectomy, coeliac disease, bacterial overgrowth and pancreatic insufficiency)

We looked at the usefulness of 23-seleno-25-homo-tauro-cholate scan (SeHCAT) in investigation of chronic diarrhoea. A retrospective analysis of 51 consecutive patients who underwent SeHCAT test was conducted. 26 of the 51 (51%) were found to have BAM as evidenced by an abnormal SeCHAT retention study. Out of the 26 positives 5 had possible type 1 abnormality (terminal ileal resection or disease) whilst the majority 19 (73%) had with type 2 abnormality (idiopathic diarrhoea). Half of those positive (53%) responded to treatment with bile acid sequestrants (BAS). This study highlights the need to consider the possibility of idiopathic bile salt malabsorption while investigating patients with diarrhoea predominant irritable bowel syndrome.

Methods: 51 patients with chronic diarrhoea who underwent SeCHAT test were studied. Clinical details were obtained from retrospective analysis of patient records. Symptoms, comorbidity and results of other investigations (colonoscopy, CRP, coeliac serology etc) were recorded. Retention of radio labelled Selenium of less than 15% at day 7 was considered as an abnormal test. Response to treatment with bile acid sequestrants (BAS) was recorded.

Results: 51 (23 male, 28 female), age range (19–85) were studied.

45 patients had idiopathic chronic diarrhoea and out of this 19 (9 males and 10 females) were found to have abnormal SeCHAT study.

There were 3 patients with previous Crohn's disease and 2 with previous intestinal resection and all 5 of these were found to have abnormal SeCHAT study. 1 patient with HIV was also found to have an abnormal test.

14 (53%) of those with abnormal SeCHAT test responded to treatment with bile acid sequestrants (BAS).

Discussion/Conclusion: It has been argued that a SeCHAT test is an expensive unnecessary test and a therapeutic trial of cholestyramine (bile acid sequestrant) would be more appropriate in those with suspected BAM. This may be an acceptable option in those with type 1 BAM ie those with terminal ileal resection and diseased terminal ileum as these patients are highly likely to have BAM. However we feel that there is still a role for this test in those with unexplained chronic diarrhoea after other common conditions have been ruled out. Compliance is likely to be better in objectively proven cases of BAM as the clinician will then be able to treat with bile acid sequestrants (BAS) with greater confidence. It also strengthens the case for continuing BAS therapy in those who respond favourably.

Whipple's disease and gastric cancer – Is there any relationship?

Cristian Searpe¹, Anca Rosu¹, Valeriu Sbarcea¹, Mihaela Tenovici²

¹Department of Internal Medicine, CF Clinical Hospital, Craiova; ²Department of Pathology, CF Clinical Hospital, Craiova, Romania

Introduction: Whipple's disease is a rare systemic condition generated by the infection with *Tropheryma whipplei*. The clinical picture is dominated by the intestinal symptoms (due to malabsorption), followed by neurological, articular, ophthalmic, pulmonary and cardiac symptoms associated with systemic lymphadenopathy and skin hyper pigmentation in the advanced stages of the disease.

Methods: We present the case of a 48 year old male operated in 1998 for cavernous cerebral hemangioma and diagnosed in 2002 with Whipple's disease. The patient had favorable evolution under long-term treatment with trimethoprim-sulfamethoxazole. In March 2009 the patient referred for polyarthralgia, weight loss and intermittent dysphagia. The superior digestive endoscopy revealed a gastric cardiac tumor with well-differentiated adenocarcinoma structure on histopathological examination of the endoscopic biopsy samples. A total gastric resection was performed with eso-jejunal transmezocolic anastomosis "a la Roux". The pathological evaluation of the resected gastric segment revealed a diffuse lymphocytic gastritis. There was no evidence of disease recurrence after 21 months of follow-up.

Discussion/Conclusion: This case emphasizes the need of further researches for a better understanding of the relation between changes of the digestive tract recorded in Whipple's disease, lymphocytic gastritis and gastric cancer development.

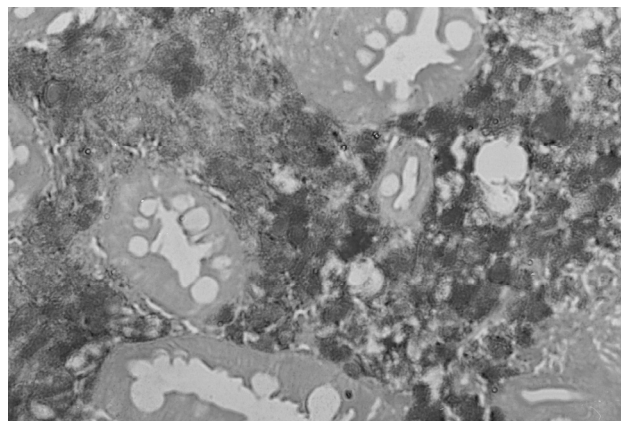


Figure 1: Histopathological examination: duodenal mucosa with high macrophage infiltration having PAS-positive cytoplasm; PAS stain, ob. x 200.

A contribution to the epidemiology of ulcerative colitis in Bulgaria

T. Karparova-Tuhchieva, P. Akrabova, V. Djurkov, V. Kuzmanov
Specialized Hospital of Gastroenterology, Plovdiv, Bulgaria

Introduction: The causes of inflammatory bowel diseases (IBD) continue to be unknown. Studies from literature show that the incidence and prevalence of IBD in Eastern Europe is increasing. In 2010 was stated that there are not exact data about the incidence of IBD in Bulgaria. There are studies revealing stable frequency of Ulcerative colitis (UC) and increasing appearance of Crohn's disease (CD). The aim of our work is to evaluate the epidemiology of UC according to the experience of our hospital.

Methods: We included in our study the patients diagnosed with UC for the period of 2008–2010. We analyzed the incidence of UC and also the following parameters: age, gender, type and severity, and provenience of the patients (urban/rural areas).

Results: There were diagnosed 47 patients with UC during this period. The age distribution was the following: 18–35 – 53.19%, 36–55 – 21.27% and > 56 – 25.53%. According to gender – 53.2% males and 46,8% females. From urban areas was 57.6%, and from rural 42.4%. According to extensiveness – 15.09% were with proctitis, 73.58% with left-sided colitis, and 22.64% with extensive or pancolitis. According to severity our patients were distributed in the following order: 62.06% with light form of activity, 31.03% with moderate, and 6.89% with severe.

Discussion/Conclusion: In our study the patients with UC were 74.29% of the patients with IBD of the hospital and 1.8% of all the patients admitted for diagnostic colonoscopy. There was a predominance of the young and medim-aged male patients from urban areas. In our group of patients there was a prevalence of distal forms of colitis with light and moderate activity.

Is Crohn's disease a rare disease?

V. Kuzmanov, T. Karparova-Tuhchieva, P. Akrabova, V. Djurkov
Specialized Hospital of Gastroenterology, Plovdiv, Bulgaria

Introduction: Crohn's disease (CD) is a lifelong disease observed predominantly in developed countries of the world. Within Europe there is a distinct North-South gradient but the incidence appears to be increased in Southern countries in recent years. In Bulgaria CD is classified in the group of rare diseases. The aim of our study is to evaluate the incidence of CD among the patients of our hospital for the period of 2008–2010.

Methods: In this study we included all the patients diagnosed with CD for the period of three years. We analyzed the frequency of appearance of CD, and also some variables as gender, age, family history, smoking habits, type of the disease.

Results: For the period of three years 18 patients with CD were diagnosed. From these cases 77.8% were male and 22.2% were female. According to age were as follows: in the group < 16 – 0%, 17–40 – 72.22% and in the group > 40 – 27.78%. According to location 10.52% were ileal, 73.68% were colonic and 10.52% – ileo-colonic. According to behavior: non-stricturing non-penetrating – 75%, stricturing – 10%, penetrating – 5%, peri-anal disease – 10%.

Discussion/Conclusion: The patients with CD were 25.71% of all the patients with IBD of the hospital, and 0.82% of the group of patients admitted for diagnostic colonoscopy. There was a predominance of the disease in young and medium aged male patients. We registered a prevalence of the colonic and non-stricturing non-penetrating forms.

Clinical and endoscopic features of patients with ulcerative colitis

A. Stadnicki^{1,2}, E. Klimacka-Nawrot¹, A. Wolańska-Karut³, I. Stadnicka⁴, J. Kurek²

¹Department of Basic Biomedical Sciences, Medical University of Silesia, Katowice, Poland; ²Section of Gastroenterology, and Department of Surgery, District Hospital, Jaworzno, Poland; ³Department of Pathology, Medical University of Silesia, Katowice, Poland; ⁴Department of Neurology, District Hospital, Sosnowiec, Poland

Introduction: It is known that indices of Crohn's disease based on clinical symptoms and laboratory findings bear little attention to the ongoing intestinal endoscopic evaluation. However in ulcerative colitis degree of relation between clinical and endoscopic picture is still controversial.

Methods: In 55 patients with UC we evaluated clinical UC activity index, according to a slight modification of Tuelove and Witts criteria, and endoscopic activity index according to Baron et al criteria: three grades of endoscopic lesions, and histological examination. In addition UC patients were divided according to colonic extension as extended to left site/total colitis or rectum/rectosigmoid colitis.

Results: Thirty of UC patients were classified as clinically active UC with score ≤ 3 (moderate/severe disease). Twenty-six of those patients have also been regarded as having endoscopic active lesions with histological confirmation. Twenty-five UC patient with clinical UC activity index ≤ 2 were regarded as inactive UC (mild disease), and 23 of those patients presented grade one of endoscopic appearance. There was strict correlation between clinical UC activity index and UC endoscopic index ($r = 0.74$, $p < 0.001$). In all investigated UC patients 19 of patients revealed left site/total colonic extension, whereas 36 patients had colitis extended to rectum/rectosigmoid. There was no relationship between colonic extension and endoscopic activity.

Discussion/Conclusion: Clinical activity index well corresponds with endoscopic activity index in UC patients.

Capsule endoscopy and pediatric IBD

Olga V. Fedorova, Elvira N. Fedulova, Galina V. Medyantseva

Federal State Institution “The Nizhny Novgorod Scientific Research Institute of Children’s Gastroenterology of Russian Ministry of Health”, Nizhny Novgorod, Russia

Some parts of the small intestines cannot be viewed through a regular endoscope, but can be viewed through a technique called Video Capsule endoscopy.

Introduction: Capsule endoscopy is of great use in the evaluation and treatment of IBD.

Methods: We used the capsule video endoscope system of Given Imaging, intestinal capsule Model PCSB-2-10-L (Israel). Capsule endoscopy allows physicians to view the entire small intestine.

Results: 32 patients 9–17 years (16 persons with Crohn’s disease, 7 with UC, 9 with small intestinal bleeding) were subjects in the study. Capsule endoscopy was performed within two weeks of colonoscopy. We have conducted 72 studies (from 1 to 5 for each patient). Patient comfort during the procedures was also recorded. In this study we found that compared to colonoscopy, capsule endoscopy was able to identify Crohn's disease (small bowel) in 44% (7 children) of patients with Crohn's disease (16 children). We conducted a survey of capsule 7 children with UC, and in 1 girl (14%) was discovered by an ulcer of the small intestine. In 9 children with obscure bleeding was discovered its cause. Capsule endoscopy led to changes in therapy for more than half of the patients studied (53%).

Discussion/Conclusion: While colonoscopy remains the gold standard for evaluation of the colon and tissue acquisition, the capsule provides an invaluable window into the sizable small bowel inaccessible by colonoscopy. The two methods are complimentary in diagnosing and treating diseases of the gastrointestinal tract.

Effective to achieve mucosal healing with infliximab in pediatric patients with Crohn's disease

J. Kierkus, M. Dadalski, G. Oracz, M. Teisseyre, M. Woynarowski, J. Ryzko
The Children's Memorial Health Institute, Warsaw, Poland

Introduction: Healing of mucosal lesions seems to be most important end point in assessment of treatment for Crohn's disease with biological agents. Simple Endoscopic Score for Crohn's Disease (SES-CD), validated in 121 CD patients^{*}, is based on 4 endoscopic variables (ulcer size, ulcerated and affected surfaces, stenosis) in 5 ileocolonic segments and the endoscopic parameters are scored from 0–3.

Aim: The aim of this study was to evaluate the efficacy of induction therapy with infliximab in children with severely active Crohn's disease using SES-CD.

Methods: We analyzed 66 children with severely active Crohn's disease (PCDAI > 30) who received infliximab 5 mg/kg at weeks 0–2–6. SES-CD was calculated for colonoscopies performed before treatment and at week 10.

Results: We have found significant decrease in SES-CD score 18; 12; 22 vs. 7.5 1; 15 [median; Q1; Q3] $p < 0.05$, between initial and control colonoscopy. 15 out of 66 patient had score 0 in control endoscopy vs. 2 out of 66 in initial one $p < 0.05$.

Discussion/Conclusion: Biological therapy with infliximab is effective to achieve mucosal healing in pediatric patients with Crohn's disease.

*Marco Daperno et al., *Gastrointestinal Endoscopy* 2004; 60 (4): 505–512.

Videocapsule and balloon-assisted enteroscopy in diagnosis of small bowel Crohn's disease

E.V. Ivanova, M.E. Timofeev, U.A. Kadnikova, E.D. Fedorov
Moscow University Hospital 31, Moscow, Russia

Introduction: Videocapsule and balloon-assisted enteroscopy are the revolutionizing techniques of the small-bowel imaging that allows substantially improve the diagnosis of small bowel Crohn's disease.

Aim of the study is to estimate the possibilities of videocapsule enteroscopy (VCE) and balloon-assisted enteroscopy (BAE) in diagnosis of Crohn's disease of the small bowel.

Methods: From V.2003 to I.2011 we observed 47 patients with definitely established small bowel Crohn's disease (18 patients – 38.3%) and strongly suspected, but rejected enteroscopically (29 patients – 61.7%). During that period 7 (14.9%) patients were operated urgently, without previous endoscopic examination because of complications. During complex examination we performed 18 VCE and 44 balloon-assisted enteroscopies (incl. 6 interventions as a follow-up in 2 cases) in 40 patients (m – 19, f – 21, ranged from 19–72 years, mean age 38.2 ± 11.9 years) with suspected Crohn's disease. There were 21 per oral and 23 per rectal examinations.

Results: During BAE in 28 patients we haven't found any signs of Crohn's disease in 17 of them [no abnormalities found (6), enteritis (9), celiac disease (1), NSAID-ulcers (1)]. Typical Crohn's disease appearance was found in 11 patients (incl. 3 patients after VCE). Conservative treatment has been applied in 7 (63.6%) patients, surgical intervention in 4 (36.4%) patients. There was a capsule retention between 2 ileum strictures in 1 (5.6%) pt. The capsule was extracted with a polypectomy snare through the enteroscope. Neither side effects or complications during BAE were observed.

Discussion/Conclusion: VCE and BAE have a major implication for diagnosis, classification, therapeutic decision making and outcomes of the Crohn's disease management.

Clinical challenge for physicians: Abdominal tuberculosis – Review of 21 cases

Meltem Ergün, Metin Başaranoğlu, Bilge Tunç, Aysel Ülker, Nurgül Şaşmaz
Türkiye Yüksek İhtisas Hastanesi Gastroenteroloji Departmanı, Ankara, Türkiye

Introduction: Abdominal tuberculosis (tb) is still seen in immune-competent adults, in developing countries. The accurate diagnosis of abdominal tuberculosis requires a high index of suspicion and combination of diagnostic modalities in clinic practice and takes a long time.

Methods: The records of 21 patients (8 females, mean age 40 years, range 21–68 years) diagnosed with abdominal tuberculosis between January 2000 and December 2010 were analyzed retrospectively. Patients' characteristics, laboratory investigations, radiological, endoscopic and surgical findings were evaluated. Follow-up information was obtained with telephone contact and scheduled visits.

Results: 21 patients were enrolled in the study. The most frequent symptoms were abdominal pain 20 (95%), fever 12 (57%), ascites 11 (52%), diarrhea 10 (47%), weight loss 9 (43%). Past history of treatment for tuberculosis was present in 7 (33%) patients. Basis of diagnosis of abdominal tb were histopathology obtained by endoscopic/colonoscopic biopsies 3 (14%), ultrasound guided biopsies 5 (24%), laparoscopic/surgical interventions 7 (33%), ascites examinations 3 (14%). Microbiological tests were positive only in 4 (19%) patients. Abdominal tb diagnosis was made by mean 2.95 ± 1 invasive procedures.

Predominant site of involvement by abdominal tb was intestinal in 10 (47%), peritoneal in 8 (38%), solid viscera/nodal in 3 (14%) cases.

Discussion/Conclusion: Intestinal tuberculosis is a complex disease with non-specific symptomatology. Combination of high index of clinical suspicion and using multiple adjuvant diagnostic tools is required to make correct diagnosis.

Intestinal tuberculosis versus Crohn's disease – Differential diagnosis and treatment issues

Sebastian Suciu, Cristian Gheorghe, Gabriel Becheanu
Gastroenterology and Hepatology Center, Fundeni, Bucharest, Romania

Background: Gastrointestinal tuberculosis and Crohn's disease may affect any part of the digestive tract with predilection for the ileocecal region. Having similar findings, there are many issues concerning the differential diagnosis of the two conditions, especially in areas with high prevalence of tuberculosis.

Materials and methods: We report 2 cases of intestinal tuberculosis in which the diagnosis was equivocal after imagistic, endoscopic and histopathologic examinations.

Results: The first case, a 65 years old female, had a history of treated pulmonary tuberculosis and bacillary sequels at pulmonary X-ray. She was admitted for low-grade fever, diffuse abdominal pain and watery diarrhea. The second case, a 39 years old male, with no history of tuberculosis, had similar but milder symptoms. At colonoscopy, erosions, hyperemia, and few aphthous ulcers in the ileo-cecal region were described in both cases, with a histopathologic aspect of non-specific inflammation, without granulomas. The Tuberculin skin test was highly positive in both cases. Tuberculosis was diagnosed in the male patient by positive Mycobacterium tuberculosis PCR assay on the ileal biopsies samples. The female patient received a trial tuberculostatic treatment for a period of 4 weeks. Afterwards, she was reviewed and a clinical and endoscopical improvement was confirmed. The initiated treatment was continued.

Conclusions: Intestinal tuberculosis and Crohn's disease share clinical, endoscopical and histological similarities. When the differential diagnosis is difficult despite extensive investigation, therapeutic antibacillary trial can be initiated. Close monitoring is required.

Five-year colonoscopic, histologic and immunohistochemical surveillance study in ulcerative colitis patients

O. Fratila, M. Puscasiu, Gratiela Avram
University of Oradea, Romania

Introduction: Long-standing ulcerative colitis (LUC) is associated with increased risk of developing colonic cancer through a dysplasia-carcinoma sequence.

Aim: to assess premalignant changes in incipient phase and to distinguish regenerative changes from dysplastic ones.

Methods: We present a 5 year dysplasia/cancer surveillance study comprising 66 patients with LUC. We used a CLE-145 Olympus videoendoscope and biopsies were taken every 10 cm throughout the colon. Routine histological examination of the H&E stained slices was made using a Carl Zeiss Ergaval light microscope (ob. x 40, ob. x 100). Additional sections were immunostained to detect nuclei positive for the proliferation marker p53 (positive p53 – > 5% stained nuclei, negative p53 – < 5% stained nuclei).

Results: Thirty patients had extensive or total and 36 left-sided colitis. In the total or extensive colitis group, 10 patients had low-grade and 3 had high-grade dysplasia. In the left-sided colitis group, 6 patients had LGD and 1 had HGD. 8 patients had indefinite dysplasia and 38 had regenerative atypia. In LGD, P53 positivity was 25% and 50% in HGD suggesting that the mutation of p53 gene is a relative early event in colorectal carcinogenesis. All regenerative atypia cases were p53 negative. Difficult cases, of “indefinite” for dysplasia were p53 negative in 75% cases.

Discussion/Conclusion: Our study stresses the importance of colonoscopy as surveillance method. The incidence of dysplasia was higher in patients with extensive colitis and increased with duration of the disease. As none of the patients studied developed colorectal cancer during the surveillance, the risk of missing cancer before becoming incurable seems low. P53 represents a useful marker where discrimination between neoplasia and regenerative epithelium is difficult, thus this technique could be trusted to improve diagnostic accuracy and to appreciate the risk of malignant transformation.

Adenomatous polyps incidence in ulcerative colitis – Comparative colonoscopic study with healthy population

Tiberia Ilias, O. Fratila, O. Straciuc
University of Oradea, Romania

Introduction: Adenomas have been established as precursors of colorectal carcinoma (CRC) in the general population. Patients with long-standing active ulcerative colitis (UC) are at risk of developing CRC. The adenoma-carcinoma sequence is generally accepted.

Aim: To compare the prevalence of left-sided adenomas in patients with IBD aged 45–65 years with a local age matched control population.

Methods: Our study comprised 48 patients with UC (25 male, 23 female) aged 45–65 years (mean age of 54 years) who underwent colonoscopy during January 2006–January 2010. The medical records were carefully reviewed to establish disease type, extent, the patient use of 5-ASA or immunosuppressant plus the identification of adenomatous polyps. The frequency of polyps was compared to that of a control group (321 healthy volunteers, aged 45–65 years). Statistical analysis was performed by use of χ^2 test.

Results: Six (12.5%) patients had extensive/pancolitis, 22 (45.8%) had left-sided disease and 20 (41.6%) patients had rectosigmoid disease. Thirty-five patients (72.9%) at the time of endoscopy were taking 5-ASA compounds, 4 patients – azathioprine, 9 patients – no drug therapy. Distal adenomas were found in 2 patients with UC compared with 38 of 321 controls (4.1% vs. 11.8%, $\chi^2 = 4.2$, $p = 0.03$).

Discussion/Conclusion: Despite the increased cancer risk in long-standing ulcerative colitis, adenomatous polyps arise less frequently in ulcerative colitis patients than in patients without ulcerative colitis. This supports the hypothesis that lesions other than polyps are important for the development of colorectal cancer in patients with IBD. These findings need to be confirmed in large prospective studies and further work is needed in the mechanism involved.

Safety and efficacy of endoscopic balloon dilation for colonic stenosis in Crohn's disease patients

C. Gheorghe, S. Suci, B. Cotruta

Center of Gastroenterology and Hepatology, Fundeni Clinical Institute, Bucharest, Romania

Objectives: Strictures are an important cause of morbidity in patients with Crohn's disease. This study was designed to investigate retrospectively the efficacy and safety of endoscopic balloon dilation for intestinal stenosis in Crohn's disease.

Method: From 119 patients with Crohn's disease, 15 cases have been diagnosed with intestinal strictures. Eight cases were treated surgically. Seven patients with 8 X-ray confirmed strictures were treated endoscopically. The topography of the stenosis was: terminal ileum (n = 1), ileocecal valve (n = 1), ileocolonic anastomosis (n = 2), left colon (n = 2), rectum (n = 2). The mean length of the stenosis was 2.75 cm (range 1–5 cm). The endoscopic maneuver was performed using through-the-scopes balloons, with diameters between 10 and 18 mm on inflation and a fixed length of 5.5 cm, under deep sedation with propofol.

Results: In 5 out of 7 patients, colonic strictures were successfully dilated in 10 sessions with complete remission of the symptoms after the first session. None of the cases had dysplasia or malignant disease on the biopsy samples taken from the stricture. The patients were followed for mean of 8 months until surgery or endoscopic control. In 1 patient with ileocolonic anastomosis stricture, a second dilation session was performed after 18 months from the first one. One of the patients, with 2 strictures dilated simultaneously, has developed a colorectal perforation, successfully resolved by surgery.

Conclusion: Using endoscopic balloon dilation for accessible colonic Crohn's disease strictures, it may be possible to avoid or postpone surgery. The procedure has an acceptable risk of complications.

Surgical management of Crohn's disease in adults: Long-term results of a tertiary center

Gurel Nessar¹, Metin Basaranoglu², Nesrin Turhan³, Bilge Tunc², Ali Eba Demirbağ¹
¹Departments of Gastrointestinal Surgery, ²Gastroenterology, and ³Pathology, Turkiye Yuksek Ihtisas Hospital, 06420 Ankara, Turkey

Introduction: Management of Crohn's disease (CD) has long been debated between gastroenterologists and surgeons. Although medical treatment options are evolving rapidly, most of these patients will eventually have the surgery in the long term. Our aim is to determine the long-term results of surgical treatment of CD in a tertiary center.

Methods: From 1991 to 2010, a total of 141 patients underwent 157 ileal, ileocolic, colonic, or anastomotic resections due to CD complications. Patients were given prophylactic treatment after bowel resection. All data was coded and recorded in SPSS for Windows version 16.0.0.

Results: Most of the patients were male (102 male, 72.3%; 39 female, 27.7%; mean age 35.2 ± 13.6 ; median 32, range: 13–74 years). Strictureing type was 63.1% (99 patients) of the cohort. Mean follow-up was 63.0 ± 45.6 months. Our study revealed that 80% of the patients were symptom-free during the follow-up period. Postoperative endoscopic recurrence encountered in 19 patients (13.5%) at the site of anastomosis or proximal bowel segment. Eight patients (5.7%) underwent second operation and 1 had 3 surgeries. Intraabdominal septic complications i.e. anastomotic leak, abscess formation or enterocutaneous fistula occurred in 19 patients (13.5%).

Discussion/Conclusion: Surgery is not only the treatment option for CD complications but also for localised ileocaecal disease with obstructive symptoms without significant evidence of active inflammation.

Key Words: Crohn's disease; complications; surgery.

Predictive validity of an accreditation assessment of colonoscopy

Elizabeth Harrison, Deepa Rattehalli, Nidhi Sagar, Monzur M. Ahmed, Chee H. Lim
Department of Gastroenterology, Good Hope Hospital, Birmingham, United Kingdom

Introduction: The Joint Advisory Group on Gastrointestinal Endoscopy (JAG) assumes a broad role in the quality assurance of endoscopy training across the UK. It defines standards for the training of all endoscopists regardless of professional background. The National Health Service (NHS) bowel cancer screening programme (BCSP) introduced a Direct Observation of Procedural Skills (DOPS) assessment for screening colonoscopists. The reliability and content validity of DOPS has been presented by JAG. Our aim was to determine the predictive validity of DOPS accreditation assessment for colonoscopy.

Methods: This review was carried out using all records, over 28 months, from the Heart of England Screening Centre. Reference was made to Quality Assurance (QA) standards specific to NHS BCSP and JAG. We compared QA standards between medically and surgically trained specialists, because it was perceived that, due to historical differences in training, trainees would not achieve the same standard. Statistical analysis was by Chi-squared, Fisher-Exact or Mann-Whitney U test.

Results: Completion rates were adjusted as there were significantly more obstructing tumours in one group. There were no significant differences in clinical QA data (adjusted completion and detection rates) supporting the predictive validity of DOPS assessment. However, there were significant differences in the parameters where the standards are not defined (median time to caecum and withdrawal time, terminal ileal intubation rates and quality of bowel preparation).

Discussion/Conclusion: DOPS accreditation has a good predictive validity for quality assurance standards for our BCSP centre. An audit of the national BCSP database may establish the proportion of colonoscopists maintaining desired QA standards.

Assessment the risk of recurrence in colonic diverticulitis

Paul Mitrut, Anca Oana Mitrut, Andreea Marinas, Amelia Genunche-Dumitrescu, Andreea Enescu, Daniela Badea
University of Medicine and Pharmacy, Craiova, Dolj, Romania

Introduction/Objectives: The incidence of acute diverticulitis is increasing in developed countries. Colonic diverticulitis shows an high recurrence rate (about 10% in the first year and then 3% per year). While in recent years a substantial agreement an medical treatment has been achieved, a large debate still exists in regards to the risk of a new episode of acute diverticulitis and risk of subsequent surgery after a first episode among patients medically or surgically treated.

Aims and methods: Our aim was to asses whether type of long treatment, endoscopic and or histological damage persistence may affect diverticulitis recurrence.

The study was performed in Second Medical Department of Emergency District Hospital from Craiova, Romania from January 2006 to December 2010 on a group of 161 patients underwent to diagnosis of acute uncomplicated diverticulitis. Statistically analysis pointed out the prevalence of males (81 patients): mean ages 56.9 years, range 36–85.

The diagnostic of acute uncomplicated diverticulitis was made in all cases by colonoscopy and abdominal computerized tomography scan. After obtaining remission, the patients were treated with mesalazine 2 g/day (81 patients, group A), or rifaximin 800 mg/day for 10 days every months (60 patients, group B), or did not take any therapy (20 patients, group C).

Patient underwent clinical, endoscopic and histological follow-up at the time of diagnosis, after 6 and thereafter every 12 months (or at the time of diverticulitis recurrence).

Results: The percentage of patients in sustained remission was statistically higher in group A (75/81; 92.5%) than group B (35/60; 58.3%) and group C (7/20; 35%) (A vs. B: $p = 0.0001$; A vs. C: $p = 0.0005$; B vs. C: $p = 0.072$).

During the follow-up, group A patients showed lower prevalence of endoscopic and histological damage then group B and group C.

Patients medically treated had a statistically significant increased probability of having a new episode of diverticulitis when in the youngest group of age, < 40 years and with increased number of episodes of acute diverticulitis before entering the study.

Conclusions: Patients taking mesalazine have lower risk of diverticulitis recurrence than patients taking rifaximin or taking no therapy. This seems to be related to the lower prevalence of persisting endoscopic and histological damage in patients taking mesalazine than in patients taking rifaximin or taking no therapy. The risk of diverticulitis recurrence is higher in patients younger than 40 years or with 3 or more previous episodes.

The colorectal involvement in lymphoma

Daniela Badea, M. Badea, Amelia Genunche, A. Badea, Laura Stefan
UMF Craiova, Dolj, Romania

Introduction: The gastrointestinal (GI) tract is the predominant site of extranodal non-Hodgkin lymphomas (NHLs). Primary NHLs of the GI tract is rare, but the secondary GI involvement is relatively common.

Methods: Our study aims to assess the incidence of primary and secondary involvement of the colon in the NHL. Endoscopic evaluation is an ideal way for verifying the extension and also for the collection of biopsy material.

Results: Between 2000–2009 our department has collected 756 NHL (except: CLL, hairy cell leukemia and mycosis fungoides). Of the 17 NHL (2.24%) with primary gastrointestinal lymphoma 14 (82.35%) had gastric involvement and only 2 (0.26% from all lymphomas) had colorectal lesions, one of the cases presented multiple lesions (gastric and colonic). Immunohistology was concordant with MALT. Endoscopic appearance was nodular lesions ulcerated in one case and infiltrative in other.

At diagnosis, secondary lymphoma involvement to the digestive tract were seen in 68 (8.99%) of patients, with only 11 with colon lesions (1.45% for all lymphoma and 16.17% from all gastrointestinal secondary lymphoma involvement).

Histological, three cases were Burkitt-like, four mantle cell lymphoma, two large cell lymphoma, three follicular lymphoma. Four cases had active HIV infection (three, Burkitt and 1 large cell lymphoma).

Endoscopic appearance was nodular and nodular ulcerative lesions in 8 cases, the other 3 cases were infiltrative appearance, two of them presenting also ulcerative lesions.

Colorectal lymphoma may present with abdominal pain 5 (45,45%), overt or occult bleeding 5 (45,45%), diarrhea 3 (27,27) or rarely, bowel obstruction (9%).

Discussion/Conclusion: Our study confirms the rarity of primary involvement of colon by lymphoma lesions. Secondary colonic lesions are more common, predominant histology were Burkitt-like/large cell (HIV+) and mantle cell lymphoma

Peutz-Jeghers syndrome

N. Taran, I. Lupaşco, V.-T. Dumbrava

State Medical and Pharmaceutical University, Chisinau, Moldova

Introduction: Peutz-Jeghers syndrome (PJS) is a hamartomatous polyposis syndrome characterized by the simultaneous presence of gastrointestinal polyposis and melanotic macules of the lips, oral mucosa and fingers. It is an autosomal dominant syndrome which appears in 1:200.000 births. PJS clinical diagnostic is suspected whether two or more Peutz-Jeghers polyps are detected in the gastrointestinal tract or one Peutz-Jeghers polyp is associated with typical pigmentation or heredocolateral antecedents of PJS.

Methods: We present a clinical case which creates difficulties in diagnostic, being a rarely met nosology.

Results: We present a patient who is 49 years old. She addressed with the following symptoms: hyperpigmentation of the lips, oral mucosa, the lower and lateral side of the tongue, hyperpigmentation of the nails of the thumb, of the 1st and the 2nd finger of the hands, hyperpigmentation of the upper side of the gum, abdominal discomfort, and constipation. Clinical-biochemical laboratory tests reflect iron deficiency anemia. At esophagogastroduodenoscopy: erosive duodenitis, erythematous reflux gastritis, the presence of eroded polyps of the body (1.0 cm) and of gastric antrum (0.6 cm). The polyps' biopsy detects unique complexes of the cells of the prismatic epithelium with moderate hypoplasia. Negative H. pylori. At the pathohistological analysis of the gastric biopsy specimen: fragments of gastric glandular polyps with edema and sporadic lymphocytic infiltration of stroma. Fibro-colonoscopy examination has showed pronouncedly twisted flexures of the colon, superficial colitis. Abdominal CT reflects indirect signs of chronic pancreatitis. Etiopathogenetic therapy initiated with: Sol. Quamateli 20 ml, i.v., 2 times/day; Sol. Fosfalugel, 1 bag 4 times/day; Sol. Ceftriaxonu 2 times/day, i.v.; Tab. Salofalk® 500 mg, 3 times/day with positive dynamics.

Discussion/Conclusion: The following case requires supervision and monitoring in dynamics due to an increased risk of malignancy: gastric, colorectal, lung, pancreatic, ovarian and breast cancer. This presentation aims to alert the doctors that Peutz-Jeghers syndrome, although is a rarely met pathology, imposes supervision in dynamics, examination of the organs with risk of malignancy as well as the necessity to examine patient's relatives.

Epidemiology of colorectal cancer in the centre of Romania

E.C. Rezi¹, A. Fraticiu¹, R. Mihaila²

¹Emergency Clinical County Hospital, Sibiu, Romania

²Medical Faculty, Lucian Blaga University, Sibiu, Romania

Introduction: Few studies have been done in order to establish the epidemiology of the colorectal cancer in Romania. Our aim was to study which is the prevalence and other epidemiological features of the colorectal cancer among the hospitalized patients from the centre of Romania.

Methods: We have performed a retrospective study on a 7 years period of observation. From the total of 7224 patients who were hospitalized on the Gastroenterology Department of the Clinical County Hospital from Sibiu, 301 were diagnosed with colorectal cancer.

Results: Among the patients hospitalized in the Gastroenterology Unit, the incidence of colorectal polyps was 16.96% from the total number of colonoscopies which were performed. Almost 7% of the polyps found at colonoscopy were with high-grade dysplasia. The colorectal cancer prevalence was 4.16% (72.66% were from urban areas and 27.34% from rural areas). The medium age of the patients with colorectal cancer was 67.28 ± 10.04 years. 28.57% of those from rural areas were diagnosed in an operable stage, while only 19.35% of those from urban areas were diagnosed in an operable stage. At those from rural areas: 14% had metastases when diagnosed and 5.71% of the tumors were invading in other organs or structures, while at those from urban areas 16.2% had metastases and 9.67% of the tumors were invading in other organs at the time of diagnosis.

Discussion/Conclusion: The prevalence of the colorectal cancer among the hospitalized patients in Gastroenterology Units from centre Romania is about 4.16%. There are significant geographic differences in colorectal cancer incidence. The majority (72%) of the patients diagnosed with colorectal cancer live in urban areas. They seem to have a poorer prognosis as they are diagnosed in more advanced stages than the others. All colorectal polyps should be excised and undergo the pathological examination. Endoscopic polypectomy can decrease the risk of colorectal cancer.

Colonoscopically monitoring of risk of recurrence after resection of colorectal carcinoma

Amelia Genunche-Dumitrescu, Daniela Badea, M. Badea, P. Mitrut
University of Medicine and Pharmacy, Craiova, Romania

Introduction: Aim of this study was colonoscopically assessment the recurrence rate of colorectal cancer after surgery treatment.

Methods: We studied 156 patients with colorectal carcinoma from Emergency Clinical Hospital Craiova. We monitor the evolution of disease and the risk of recurrences after surgical treatment at 6, 12, 24 and 36 months. The examination was based of clinical manifestations, colonoscopy with biopsy criteria. Statistical analysis use Wilcoxon and Kruskal-Wallis test.

Results: 88 patients with colorectal cancer (52 males and 36 females) underwent surgical treatment. The type of adenocarcinoma was: papillary in 15 cases, tubular (49 cases), mucinous (12 cases), villous (5 cases) and undifferentiated (7 cases). Most of those patients had Duke's B stage (38 cases) or C stage (34 cases) tumors. The localization of carcinoma was: right colon 19 cases, transverse colon 7 cases, left colon 13 cases, sigmoid 20 cases and rectum 29 cases. The 38 patients had cancer recurrences: 3 patients after 6 months, 9 patients after 1 year, 16 patients after 24 and 10 patients within 36 to 40 months. All recurrences in patients with initial stage I disease were local and regional, where 14 of 19 recurrences in stage II disease were distant. Two recurrences were detected at 6 patients during separate examinations and 3 recurrences in 2 patients in 1 examination. Local recurrence occurs more frequently in sigmoid (55.0%) and rectal cancers (62.07%). Lower stage was associated with higher adenoma recurrence rates ($p = 0.04$). Factors including age, sex and clinical manifestations were not significantly correlated with recurrence rates.

Discussion/Conclusion: Local recurrence occurs more frequently in sigmoid and rectal carcinoma. The rate of recurrence was correlated with Duke's stage. The routine colonoscopy is capable of early tumor detection.

The characteristics of non-curative endoscopic resection in early colon cancer

Jin Yong Kim, Sung June Eo, Dong Kyung Chang, Young-Ho Kim, Poong-Lyul Rhee, Jae J. Kim

Department of Medicine, Samsung Medical Center, Sungkyunkwan University School of Medicine, Seoul, Republic of Korea

Introduction: Endoscopic resection could be a curative treatment option for selected early colon cancer without lymph node metastasis. However, in case of positive resection margin and probable lymph node metastasis, additional surgery is needed for safety reason. The aim of this study is to find the characteristics of patients who needs additional treatment and to figure out the factor of residual tumor and lymph node metastasis.

Methods: Between January 2001 and April 2010, 85 additional surgery had been performed after endoscopic resection for early colon cancer at our department.

Results: The reasons for additional surgery are submucosal invasion over 1000 micrometer (76 patients, 89.4%), positive lateral margin (21 patients, 24.7%) or vertical resection margin (25, 29.4%) Also, patients who had surgery due to lymphatic invasion or vascular invasion are 15 patients (17.6%) and 17 patients (20.0%) respectively. Number of the patients with non-lifting sign is 11 (12.9%). In the positive lateral margin group, there are no significant differences in the residual tumor rate and lymph node metastasis.

However, residual tumor and lymph node metastasis rate are higher in the positive vertical margin group ($p = 0.015$) and the odds ratio was 15.23. In the patients with non-lifting sign, the odds ratio is 13.52 ($p = 0.013$).

Discussion/Conclusion: Endoscopic resection is safe and effective modality of treatment option in most selected cases of early colon cancer. However, in case with positive vertical resection margin and positive non-lifting sign, additional surgery should be considered because of the high risk of residual tumor and lymph node metastasis.

Adherence to colorectal cancer (CRC) guidelines after polypectomy in a university hospital

Beate Zimmer, Jörg Felber, Andreas Stallmach
Department of Gastroenterology, Hepatology and Infectious Diseases, Jena University Hospital, Jena, Germany

Introduction: CRC is the second most common malignancy in Germany. Screening colonoscopies with polypectomy have been demonstrated to reduce the incidence of CRC. Detailed recommendations on scheduling screening and follow up colonoscopies have therefore been included into national guidelines. Knowledge about CRC-guidelines and adherence to guideline recommendations varies greatly among physicians.

Methods: We combined different implementation strategies (training-courses, case-discussion, handouts, wall-charts) to improve adherence of recommendations for scheduling follow-up colonoscopy. To assess adherence, written recommendations given at discharge after inpatient treatment for polypectomy were analyzed before (n = 111) and after (n = 83) the conduction of the above mentioned implementation measures. Additional factors possibly influencing the recommendations of physicians were collected (histology, polyp size).

Results: The adherence to the CRC-guideline before conduction of above mentioned measures was moderate. After intervention, there was a non-significant increase from 47% to 53%. Senior physician review and editing of the discharge summaries improved guideline adherence of recommendations to 68%. Neither the education level of residents nor their affiliation to a certain department had an impact on the quality of the recommendations. Histology and complete versus incomplete resection of polyps had an influence of the recommended schedule. Further, size of the polyps, but not the number, had a statistically significant influence on the quality of the recommendations.

Discussion/Conclusion: The inadequate improvement of guideline adherence can possibly be explained by insufficient interactive and repetitive character of interventions. As the histology have an influence on the recommendations in regards to the interval to the next colonoscopy, interdisciplinary teaching is necessary to improve guideline concurrent care.

Impact of a routine weekend endoscopy service on patients presenting with upper gastrointestinal bleeding

A. Vaishnavi^{1*}, C. Ash¹, S. Singh², K. Padmakumar²

¹Gastroenterology Unit, Royal Bolton NHS Trust, ²Royal Bolton NHS Trust, Consultant, Gastroenterologist, Bolton, United Kingdom

Introduction: SIGN guidelines advocate inpatient gastroscopy for patients presenting with symptoms and signs of gastrointestinal (GI) bleeding and a pre-endoscopy (initial) Rockall score ≥ 1 [1]. Patients admitted over a weekend may experience delays because most units only offer emergency services over a weekend. In 2009, the Royal Bolton Hospital set up routine weekend lists with allocated capacity for patients requiring urgent gastroscopy. We evaluated the impact of this weekend service on patients presenting with signs of gastrointestinal bleeding.

Methods: Data was collected prospectively on all patients presenting with GI bleeding over a 3 month period between April and July 2010. We collected the pre endoscopy Rockall score and time to endoscopy. Results were compared with a historical audit over 4 months from October 2005 to January 2006. The percentage of weekday (Monday 09:00–Friday 17:00) and weekend admissions (Friday 17:00–Monday 09:00) undergoing endoscopy within 24 hours was compared between the two time periods. Economic analysis was based on extra costs incurred in the current system.

Results: Fifty two patients presented with upper GI bleeding with over half ($n = 27$) presenting over a weekend. Overall 61.5% patients underwent endoscopy within 24 hours in 2010, compared with 58% in 2005. The corresponding percentage for weekday admissions was 64% (2010) and 62% (2005). Over the weekend, a more obvious discrepancy 59% (2010) and 48% (2005). 96% of weekend admissions underwent endoscopy within 48 hours in 2010.

Seven of the 27 weekend admissions had a Rockall score of 0 while 10 had scores ≥ 3 . Of these 10, 6 had endoscopy performed within 24 hours and 9 within 48 hours. 20 endoscopies were performed over the weekend of which 4 had a Rockall score of 0 and 8 had scores ≥ 3 .

Discussion/Conclusion: There has been an improvement in the time to endoscopy, especially over the weekend and this appears to be a result of the new service. 20% of the endoscopies performed over the weekend had a Rockall score of 0 despite evidence that these patients could have been safely discharged. The availability of this service may have pushed the medical on call team to send low risk patients prior to discharge rather than using the slots more appropriately. The importance of Rockall score in risk stratification and the timing of endoscopy needs to be widely disseminated along with a strict algorithm for out of hours endoscopy. The financial impact of this service has been more than offset by the extra capacity for routine endoscopy and is valued by patients who prefer not to take time off work. The impact on “out of hours” endoscopy, length of stay and mortality needs to be evaluated further.

1. *Management of acute upper and lower gastrointestinal bleeding*, SIGN, 2008. <http://www.sign.ac.uk/pdf/sign105.pdf>

Early gastric cancer (EGC) – An incidental finding in the upper GI bleeding. Case report

A. Bartkova¹, M. Liberda¹, O. Urban²

¹Valasske Mezirici Hospital, Valasske Mezirici, Czech Republic

²Vitkovice Hospital, Ostrava, Czech Republic

Introduction: Gastric carcinoma is the second most common cause of the world's cancer-related death and the only solid cancer with the decreasing incidence over the past decades. Its prognosis remains poor, since its manifestation is delayed and the diagnosis is usually made in the late stages. The diagnosis in the stage of so-called early gastric cancer (EGC), limited to the musosa and the submucosa (T1m and T1sm stages), is the most influential prognostic factor for survival.

Case description and results: We present our own experience with the diagnosis of EGC. In September 2008, 76 years old woman presented with recurrent upper GI bleeding, only the third gastroscopy revealed diminutive gastric angiodysplasia as the source of bleeding (treated by argon plasma coagulation) and the incidental finding of EGC. She was subsequently provided with the therapeutic endoscopy (ESD) with the curative result.

Discussion: Early diagnosis of EGC in Europe constitutes less than 10%, while in Japan with a national gastric cancer screening programme since 70s', this diagnosis is made in up to 50% of patients. The risk of lymph node metastases in mucosal cancer is low (0–3%), it increases significantly with submucosal invasion (14–25%). Endoscopic treatment of EGC is possible either by endoscopic mucosal resection (EMR) or by endoscopic submucosal dissection (ESD). These miniinvasive techniques enable a curative procedure even in the elderly and/or patients who are poor candidates of surgical resection. In a subgroup of patients with upper GI bleeding, second- (or third) look gastroscopy may be necessary to reveal additional pathological findings.

Rectorrhagia – The etiology and the clinical spectrum

Dana Damian, Cristina Pojoga
Third Medical Clinic, Cluj Napoca, Romania

Introduction: Lower gastrointestinal bleeding continues to represent an important cause for hospitalized morbidity and mortality.

Aim: To evaluate the etiology in patients with rectorrhagia.

Methods: From a total of 4792 patients admitted in our department on 2005, 121 subjects (2.5%) were diagnosed with rectorrhagia and underwent colonoscopy for diagnosis. We analysed the demographical and etiological data on different patient groups, the cut-off value being 50 years, as a limit age for colonoscopy screening indication.

Results: The etiology of rectorrhagia was as follows: hemorrhoids (38.84%), hemorrhoids and other diseases (8.26%) and non-hemorrhoidal (52.89%). The last patients group have many causes: inflammatory bowel diseases (43.94%), colorectal cancer (22.73%), diverticulosis (7.58%), postpolypectomy (6.06%), irradiation (6.06%), ischemic (3.03%) and infectious (3.03%) colitis, anal fissures (3.03%) and no evident cause (1.52%).

Diarrhea was more common in patients with non-hemorrhoidal bleeding (54.69% vs. 17.02%, $p = 0.00005$) and the constipation has an increased frequency in patients with hemorrhoidal bleeding (38.3% vs. 14.06%, $p = 0.003$). According age, rectorrhagia due to inflammatory bowel diseases was more frequent in patients under 50 years (18.18% vs. 8.26%, $p = 0.022$) and the colorectal cancer in the second (9.92% vs. 2.48%, $p = 0.016$).

Discussion/Conclusion: Inflammatory bowel diseases and colorectal cancer were more important etiological causes in the non-hemorrhoidal bleeding in two different age groups.

Diarrhea and constipation were more common clinical manifestations in patients with non-hemorrhoidal/hemorrhoidal bleeding.

Mechanism of action for Ankaferd Blood Stopper (ABS) in patients with gastrointestinal hemorrhages

Yavuz Beyazit, Metin Basaranoglu

Department of Gastroenterology, Turkiye Yuksek Ihtisas Training and Research Hospital, Ankara, Turkey

Background and aim: Gastrointestinal (GI) bleeding refers to any hemorrhage from the mouth to the anal canal. Despite the recent improvements in the endoscopic hemostatic and adjuvant pharmacologic management, the reported mortality is still around 5–10% for peptic ulcer bleeding and about 15–20% for variceal hemorrhages.

Material/Methods: Ankaferd Blood Stopper (ABS) is a recently approved topical hemostatic agent. Through its effects on the endothelium, blood cells, angiogenesis, cellular proliferation, vascular dynamics, and wound healing, ABS is now becoming an effective alternative hemostatic medicine for gastrointestinal bleedings that are resistant to conventional anti-hemorrhagic measurements. We explain the underlying mechanisms of ABS in patients with upper GI bleeding. Figure show that the basic mechanism of action for Ankaferd Blood Stopper (ABS) is the formation of an encapsulated protein network that provides focal points for erythrocyte aggregation. ABS-induced formation of the unique protein network within the vital erythroid aggregation covers the entire physiological haemostatic process.

Conclusions: Red blood cell (RBC) elements (such as spectrin and ankrin surface receptors, and internal ferrochelatase enzyme), related transcription factors (such as GATA-1) and RBC-related proteins (such as urotensin II) are the main targets of ABS. Those proteins and the required ATP bioenergy are included in the protein library of Ankaferd.

Ankaferd hemostat for the management of upper gastrointestinal hemorrhages: A meta-analysis

Metin Basaranoglu, Yavuz Beyazit

Department of Gastroenterology, Turkiye Yuksek Ihtisas Training and Research Hospital, Ankara, Turkey

Background and aim: Gastrointestinal (GI) bleeding refers to any hemorrhage ascribed to the pathologies of the gastrointestinal tract, extending from the mouth to the anal canal. Despite the recent improvements in the endoscopic hemostatic and adjuvant pharmacologic management, the reported mortality is still around 5–10% for peptic ulcer bleeding and about 15–20% for variceal hemorrhages. Ankaferd Blood Stopper (ABS) is a recently approved traditional topical hemostatic agent. Through its effects on the endothelium, blood cells, angiogenesis, cellular proliferation, vascular dynamics, and wound healing.

Material/Methods: We analyzed 11 studies for this meta-analysis.

Results: Shown in Table 1.

Conclusion: ABS may serve as an adjuvant and/or primary agent and now becoming an effective alternative hemostatic medicine for gastrointestinal bleedings that are resistant to conventional anti-hemorrhagic measurements which prompting potential future controlled trials in this complicating field.

Table 1: Current data regarding the use of ABS in distinct states of GI bleedings

Reference	Year	Number of Patients (n)	Diagnosis	Mean ABS Volume (ml)
Kurt et al.	2008	1	Dieulafoy lesion	12
Kurt et al.	2008	1	Distal cholangiocellular carcinoma	15
Tuncer et al.	2009	1	Fundal variceal bleeding	6
Kurt et al.	2009	7	Gastric cancer	9.7
Ozaslan et al.	2009	5	Gastric cancer	8
		1	Periampullary cancer	10
Beyazit et al.	2010	1	Sphincterotomy bleeding	3
Ozaslan et al.	2010	1	Variceal bleeding	10
Karaman et al.	2010	2	Gastric postpolypectomy bleeding	5–6
Karaman et al.	2010	1	Oozing visible vessel at duodenum	5
Kurt et al.	2010	6	Gastric postpolypectomy bleeding	10
Kurt et al.	2010	2	Duodenal postpolypectomy bleeding	9.5
Kurt et al.	2010	4	Gastric biopsy	10
Kurt et al.	2010	2	Dieulafoy lesion	47
Kurt et al.	2010	2	GAVE	15
Kurt et al.	2010	1	Congestive gastropathy	10
Ozaslan et al.	2010	5	Peptic ulcer	7.2
Ozaslan et al.	2010	2	Acute erosive gastropathy	5.5
Ozaslan et al.	2010	1	Esophageal ulcer	7
Ozaslan et al.	2010	1	Mallory-Weiss	13
Purnak et al.	2010	1	Peptic ulcer	20
Zulfikar et al.	2010	1	Esophageal cancer	6

Application of Ankaferd Blood Stopper for gastrointestinal system bleeding

Mevlut Kurt¹, Abdurrahim Sayilir¹, Yavuz Beyazit¹, Murat Kekilli¹, Ibrahim Koral Onal¹
¹Department of Gastroenterology, Turkiye Yuksek Ihtisas Teaching and Research Hospital, Ankara, Turkey

Introduction: The aim of this study was to evaluate the efficacy of Ankaferd Blood Stopper in the management of persistent upper and lower gastrointestinal bleeding despite the use of conventional methods of hemostasis.

Methods: The records of 22,215 patients who underwent upper and lower endoscopy procedures in our hospital between July 2009 and December 2010 were reviewed. Patients, in whom ABS was used as an adjuvant hemostatic agent, where conventional methods failed to achieve hemostasis, were included in the study.

Results: ABS was applied in 19 patients with a total of 21 procedures. Indications for use included esophagus variceal bleeding (n = 5), Dieulafoy's lesion (n = 3), postpolypectomy bleeding (n = 4), tumoral bleeding (n = 3), ulcer bleeding (n = 4) and Mallory-Weiss tear (n = 1). ABS was successful in controlling the bleeding in 16 patients, failing in 3. The first was a patient with esophagus varices in whom recurrence of bleeding prompted TIPS placement. Another patient with post-polypectomy bleeding had to be referred for surgery. A patient who had undergone a Whipple operation for pancreatic cancer developed bleeding from an anastomotic ulcer. Angiographic evaluation revealed the presence of a pseudoaneurysm below the right hepatic artery, as well as findings consistent with small bowel fistulization. This patient was the only reported fatality.

Discussion/Conclusion: Current knowledge dictates that ABS should only be used as a last resort after conventional endoscopic modalities fail, and even then its role should be reserved as an adjuvant agent. The true efficacy of ABS can only be established by randomized controlled studies comparing it with other modalities of hemostasis.

UK endoscopy trainees provide a significant quantity of service delivery

L.P. Griffiths¹, K. Dowler², R. Valori¹, P. Dunckley¹

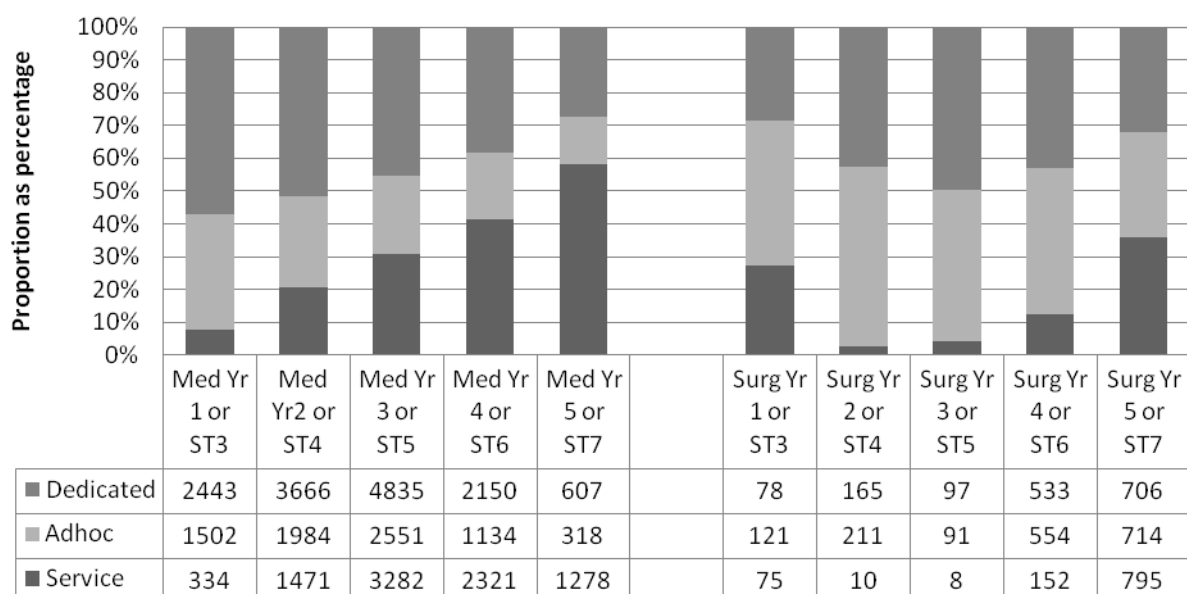
¹Gastroenterology, ²IT, Gloucester Royal Hospital, Gloucester, United Kingdom

Introduction: In September 2009, the JAG Endoscopy Training System (JETS) e-portfolio was launched. Since its release, over 75% of UK trusts have set the system up and over 70,000 procedures logged. Within the JETS e-portfolio, trainees record their data under pre-defined lists. These are dedicated training lists, ad-hoc training lists (training occurring on a standard service list) or service lists. With the European Working Time Directive, trainees have less opportunity for endoscopy training. We studied the proportion of endoscopies performed on each of the list types by trainees to assess when trainees start to provide service lists within the NHS.

Methods: All endoscopy data from the JETS e-portfolio from September 2009 to 30th October 2010 were analysed.

Results: 60,124 endoscopies were performed by trainees; 22,358 (37%) on service lists. 34,186 endoscopies were performed by registrar-level doctors, and 9726 (28%) of these were on service lists [Figure 1]. The remaining 25,938 endoscopies, of which 12,632 were service (47%), were performed by others such as associate specialists and nurse endoscopists.

Figure 1: 100% stacked column of registrar-level endoscopy procedure type expressed proportionally, split by year of training and specialty, with total endoscopy numbers below



Discussion/Conclusion: UK trainee endoscopists contribute towards a large volume of service provision; in fact by year 5, gastroenterology registrars perform the majority of their endoscopies on service lists. This data shows that hospital trusts should prioritise endoscopy training. High quality training will result in competent, experienced, independent trainee endoscopists who can support the service of the trust in which they work and gain further valuable experience.